

# Wilms Tumor (Nephroblastoma), Version 2.2021

Frank Balis, MD<sup>1,\*</sup>; Daniel M. Green, MD<sup>2,\*</sup>; Clarke Anderson, MD<sup>3</sup>; Shelly Cook, MD<sup>4</sup>; Jasreman Dhillon, MD<sup>5</sup>; Kenneth Gow, MD, MHA<sup>6</sup>; Susan Hiniker, MD<sup>7</sup>; Rama Jasty-Rao, MD<sup>8</sup>; Chi Lin, MD, PhD<sup>9</sup>; Harold Lovvorn III, MD<sup>10</sup>; Iain MacEwan, MD<sup>11</sup>; Julian Martinez-Agosto, MD, PhD<sup>12</sup>; Elizabeth Mullen, MD<sup>13,\*</sup>; Erin S. Murphy, MD<sup>14</sup>; Mark Ranalli, MD<sup>15</sup>; Daniel Rhee, MD, MPH<sup>16</sup>; Denise Rokitka, MD, MPH<sup>17</sup>; Elisabeth (Lisa) Tracy, MD<sup>18</sup>; Tamara Vern-Gross, DO<sup>19</sup>; Michael F. Walsh, MD<sup>20</sup>; Amy Walz, MD<sup>21,\*</sup>; Jonathan Wickiser, MD<sup>22,\*</sup>; Matthew Zapala, MD, PhD<sup>23</sup>; Ryan A. Berardi, MSc<sup>24</sup>; and Miranda Hughes, PhD<sup>24</sup>

## ABSTRACT

The NCCN Guidelines for Wilms Tumor focus on the screening, diagnosis, staging, treatment, and management of Wilms tumor (WT, also known as nephroblastoma). WT is the most common primary renal tumor in children. Five-year survival is more than 90% for children with all stages of favorable histology WT who receive appropriate treatment. All patients with WT should be managed by a multidisciplinary team with experience in managing renal tumors; consulting a pediatric oncologist is strongly encouraged. Treatment of WT includes surgery, neoadjuvant or adjuvant chemotherapy, and radiation therapy (RT) if needed. Careful use of available therapies is necessary to maximize cure and minimize long-term toxicities. This article discusses the NCCN Guidelines recommendations for favorable histology WT.

*J Natl Compr Canc Netw* 2021;19(8):945-977  
doi: 10.6004/jnccn.2021.0037

<sup>1</sup>Abramson Cancer Center at the University of Pennsylvania; <sup>2</sup>St. Jude Children's Research Hospital/The University of Tennessee Health Science Center; <sup>3</sup>City of Hope National Medical Center; <sup>4</sup>University of Wisconsin Carbone Cancer Center; <sup>5</sup>Moffitt Cancer Center; <sup>6</sup>Fred Hutchinson Cancer Research Center/Seattle Cancer Care Alliance; <sup>7</sup>Stanford Cancer Institute; <sup>8</sup>University of Michigan Rogel Cancer Center; <sup>9</sup>Fred & Pamela Buffett Cancer Center; <sup>10</sup>Vanderbilt-Ingram Cancer Center; <sup>11</sup>UC San Diego Moores Cancer Center; <sup>12</sup>UCLA Jonsson Comprehensive Cancer Center; <sup>13</sup>Dana-Farber/Brigham and Women's Cancer Center; <sup>14</sup>Case Comprehensive Cancer Center/University Hospitals Seidman Cancer Center and Cleveland Clinic Taussig Cancer Institute; <sup>15</sup>The Ohio State University Comprehensive Cancer Center - James Cancer Hospital and Solove Research Institute; <sup>16</sup>The Sidney Kimmel Comprehensive Cancer Center at Johns Hopkins; <sup>17</sup>Roswell Park Comprehensive Cancer Center; <sup>18</sup>Duke Cancer Institute; <sup>19</sup>Mayo Clinic Cancer Center; <sup>20</sup>Memorial Sloan Kettering Cancer Center; <sup>21</sup>Robert H. Lurie Comprehensive Cancer Center of Northwestern University; <sup>22</sup>UT Southwestern Simmons Comprehensive Cancer Center; <sup>23</sup>UCSF Helen Diller Family Comprehensive Cancer Center; and <sup>24</sup>National Comprehensive Cancer Network.

\*Discussion Writing Committee Member.

## NCCN CATEGORIES OF EVIDENCE AND CONSENSUS

**Category 1:** Based upon high-level evidence, there is uniform NCCN consensus that the intervention is appropriate.

**Category 2A:** Based upon lower-level evidence, there is uniform NCCN consensus that the intervention is appropriate.

**Category 2B:** Based upon lower-level evidence, there is NCCN consensus that the intervention is appropriate.

**Category 3:** Based upon any level of evidence, there is major NCCN disagreement that the intervention is appropriate.

**All recommendations are category 2A unless otherwise noted.**

**Clinical trials:** NCCN believes that the best management of any patient with cancer is in a clinical trial. Participation in clinical trials is especially encouraged.

## PLEASE NOTE

The NCCN Clinical Practice Guidelines in Oncology (NCCN Guidelines<sup>®</sup>) are a statement of evidence and consensus of the authors regarding their views of currently accepted approaches to treatment. Any clinician seeking to apply or consult the NCCN Guidelines is expected to use independent medical judgment in the context of individual clinical circumstances to determine any patient's care or treatment. The National Comprehensive Cancer Network<sup>®</sup> (NCCN<sup>®</sup>) makes no representations or warranties of any kind regarding their content, use, or application and disclaims any responsibility for their application or use in any way.

© National Comprehensive Cancer Network, Inc. 2021. All rights reserved. The NCCN Guidelines and the illustrations herein may not be reproduced in any form without the express written permission of NCCN.

## Disclosures for the NCCN Wilms Tumor (Nephroblastoma)

At the beginning of each NCCN Guidelines Panel meeting, panel members review all potential conflicts of interest. NCCN, in keeping with its commitment to public transparency, publishes these disclosures for panel members, staff, and NCCN itself.

Individual disclosures for the NCCN Wilms Tumor (Nephroblastoma) Panel members can be found on page 977. (The most recent version of these guidelines and accompanying disclosures are available at NCCN.org.)

**The complete and most recent version of these guidelines is available free of charge at NCCN.org.**

## INTRODUCTION TO WILMS TUMOR

All patients with suspected Wilms tumor (WT) should be managed by a multidisciplinary team with experience managing renal tumors; consulting a pediatric oncologist is strongly encouraged.

*The NCCN Guidelines for Wilms Tumor (Nephroblastoma) only address favorable histology Wilms tumor (FHWT) at this time.*

**Epidemiology of Wilms Tumor**

- WT accounts for 5% of childhood cancers and is the most common primary renal tumor in children (accounts for >90% of renal tumors in patients <20 years). Five-year survival for these patients is >90% with appropriate treatment. However, outcome of some groups, particularly those with diffuse anaplastic WT, remains poor. This guideline does not include anaplastic WT at this time.
- Incidence of WT is highest among African American children, followed by Caucasian children, and children of Asian descent have the lowest incidence.<sup>1</sup>
- >75% of WT present between 1–5 years (most commonly 3 years).<sup>2</sup>
- Most patients have a solitary tumor at presentation. However, 5%–13% have bilateral tumors, and 10% have multifocal tumors in a single kidney.<sup>3–6</sup>
  - ▶ For unilateral tumors, the median age at diagnosis is 35 months for boys, and 42 months for girls.<sup>1</sup>
  - ▶ For bilateral tumors, the median age at diagnosis is 23 months for boys, and 28.5 months for girls.<sup>1</sup>

**Clinical Presentation**

- Most patients present with abdominal distention and/or presence of an abdominal mass (83%) with or without abdominal pain (37%), fever (23%), hematuria (21%–25%), and hypertension (20%–25%). Less common symptoms include: varicocele, hernia, enlarged testicle, congestive heart failure, hypoglycemia, Cushing syndrome, pleural effusion, and acute abdomen.
- A healthy-appearing child is more likely to have WT, whereas an ill-appearing child may have neuroblastoma.
- Calcification of the tumor appears in approximately 5%–10% of WTs, versus approximately 60%–70% of neuroblastomas.
- Almost 10% of patients with WT have coagulopathy (acquired Von Willebrand disease).<sup>7–9</sup>
- Most common sites of hematogenous metastases include: lung (81%), lung and liver (15%), other (4%).<sup>10</sup> Spread to regional lymph nodes (LNs) also occurs.
- WT is associated with genetic predisposition syndromes, such as Beckwith-Wiedemann syndrome (macroglossia, hemihyperplasia, gigantism, and umbilical hernia); WAGR syndrome (WT, aniridia, genitourinary abnormalities, and range of developmental delay); and Denys-Drash syndrome (male pseudohermaphroditism and glomerulopathy), in 10%–15% of cases.<sup>11–15</sup>
- Aniridia is present in 1% of children with WT, and hemihyperplasia appears in 2%–3% of WT patients.<sup>15–17</sup>
- Genitourinary malformations (ie, cryptorchidism, hypospadias, fused [horseshoe] kidneys) are found in 5% of patients with WT.<sup>17,18</sup>
- If predisposition is present, routine screening for WT is recommended with physical exam and renal US every 3 months until at least 8 years of age.<sup>19,20</sup>
- Children with multifocal/bilateral disease present at a younger age than children with unilateral disease, and are often identified as part of a surveillance program.<sup>19,20</sup>

**Treatment**

- Treatment for WT ranges from observation after surgery only, to intensive chemotherapy, radiation, and surgery, depending on whether the WT is unilateral or bilateral, local stage, presence of metastases, patient age, tumor weight, biologic risk factors, histology, and clinical response to therapy.
- Consulting a radiation oncologist is recommended at time of diagnosis of WT.
- Studies of long-term survivors show these therapies are effective; however, judicious use of available therapies is necessary to maximize cure while minimizing long-term toxicities.
- Appropriate assignment of therapy to balance these goals employs an evolving system of risk stratification.
- Referral to Cancer Predisposition Consultation is appropriate for all patients with WT and strongly encouraged for patients with multifocal or bilateral WT.
- Recommend referral to infertility risk/fertility preservation counseling for all patients treated with chemotherapy; strongly encourage prior to treatment with regimens M or whole abdominal irradiation (WAI).<sup>21,22</sup>

Version 2.2021, 06/17/21 © National Comprehensive Cancer Network, Inc. 2021. All rights reserved.  
The NCCN Guidelines® and this illustration may not be reproduced in any form without the express written permission of NCCN.

INTRO-1

**Overview**

Wilms tumor (WT, also known as nephroblastoma) is the most common primary renal tumor in children. In the United States, approximately 650 children are diagnosed with WT each year.<sup>1</sup> WT accounts for more than 90% of primary renal tumors in patients younger than 20 years and for 5% of all childhood cancers. Most children (75%) present with WT between 1 and 5 years of age, most commonly at 3 years.<sup>1,2</sup> The incidence of WT is highest among African American children, followed by Caucasian children, and then Asian children.<sup>3–6</sup> Five-year survival is more than 90% for children with all stages of favorable histology WT (FHWT) who receive appropriate treatment.<sup>7–10</sup> However, survival remains poor for children with higher-stage diffuse anaplastic WT.<sup>11,12</sup> Most children present with resectable disease in one kidney, and upfront unilateral nephrectomy is recommended for most children.<sup>9</sup> These NCCN Guidelines for Wilms Tumor (Nephroblastoma) were first published in 2021 and only address FHWT at this time. These NCCN Guidelines will be updated at least once a year by the NCCN Wilms Tumor Panel.

**Clinical Presentation**

There are 2 primary ways children can be diagnosed with WT. Most children present with signs suggesting the presence of a renal condition, including abdominal swelling and/or a suspicious mass (see “Presentation,” WILMS-1 in the algorithm). Many of these children are asymptomatic, and the abdominal mass is discovered by a caretaker during routine activities such as bathing, or during examination by a pediatrician. Importantly, the abdominal mass should not be vigorously or frequently palpated to avoid rupturing the tumor. The other method of detection is through planned radiologic screening for children who have been identified as having a genetic predisposition condition and/or congenital anomalies (see “Genetic Predisposition Conditions,” page 947). Tumors discovered on routine imaging are almost always small asymptomatic lesions. Other rare presentations are found incidentally at surgery for another cause (eg, trauma, appendicitis).

Most children present with a solitary tumor in one kidney. However, 5%–13% of children have bilateral tumors and 10% have multifocal tumors in a single kidney. Most patients present with abdominal swelling and/or presence of an abdominal mass (83%) with or without abdominal

INTRODUCTION TO WILMS TUMOR  
REFERENCES

- <sup>1</sup> Steliarova-Foucher E, Colombet M, Ries LAG, et al. International incidence of childhood cancer, 2001-10: a population-based registry study. *Lancet Oncol* 2017;18:719-731.
- <sup>2</sup> Howlander N, Noone AM, Krapcho M, et al. SEER Cancer Statistics Review, 1975-2017, based on November 2019 SEER data submission, posted to the SEER web site, April 2020. Bethesda, MD: National Cancer Institute; 2020.
- <sup>3</sup> D'Angio GJ. National Wilms' Tumor Study, Seattle, WA: NWTS Data and Statistical Center: 1991 [Informational Bulletin #19].
- <sup>4</sup> Breslow NE, Churchill G, Nesmith B, et al. Clinicopathologic features and prognosis for Wilms' tumor patients with metastases at diagnosis. *Cancer* 1986;58:2501-2511.
- <sup>5</sup> Hadley GP, Jacobs C. The clinical presentation of Wilms' tumour in black children. *S Afr Med J* 1990;77:565-567.
- <sup>6</sup> Ehrlich P, Chi YY, Chintagumpala MM, et al. Results of the first prospective multi-institutional treatment study in children with bilateral Wilms tumor (AREN0534): A report from the Children's Oncology Group. *Ann Surg* 2017;266:470-478.
- <sup>7</sup> Green DM. Diagnosis and management of malignant solid tumors in infants and children. 1985. Martinus Nijhoff Publishing, Boston, MA.
- <sup>8</sup> Maas MH, Cransberg K, van Grotel M, et al. Renin-induced hypertension in Wilms tumor patients. *Pediatr Blood Cancer* 2007; 48:500-503.
- <sup>9</sup> Marsden HB, Lawler W, Kumar PM. Bone metastasizing renal tumor of childhood: morphological and clinical features, and differences from Wilms' tumor. *Cancer* 1978; 42:1922-1928.
- <sup>10</sup> Ehrlich PF, Ferrer FA, Ritchey ML, et al. Hepatic metastasis at diagnosis in patients with Wilms tumor is not an independent adverse prognostic factor for stage IV Wilms tumor: a report from the Children's Oncology Group/National Wilms Tumor Study Group. *Ann Surg* 2009;250:642-648.
- <sup>11</sup> Dome JS, Huff V. Wilms Tumor Predisposition. *GeneReviews*® [Internet] <https://www.ncbi.nlm.nih.gov/books/NBK1294>.
- <sup>12</sup> Grundy P, Coppes M. An overview of the clinical and molecular genetics of Wilms' tumor. *Med Pediatr Oncol* 1996;27:394-397.
- <sup>13</sup> Blakely ML, Ritchey ML. Controversies in the management of Wilms tumor. *Semin Pediatr Surg* 2001;10:127-131.
- <sup>14</sup> Douglass EC, Look AT, Webber B, et al. Hyperdiploidy and chromosomal rearrangements define the anaplastic variant of Wilms' tumor. *J Clin Oncol* 1986;4:975-981.
- <sup>15</sup> Riccardi VM, Hittner HM, Francke U, et al. The aniridia-Wilms' tumor association: The critical role of chromosome band 11p13. *Cancer Genet* 1980;2:131-137.
- <sup>16</sup> Palmer N, Evans AE. The association of aniridia and Wilms' tumor: methods of surveillance and diagnosis. *Med Pediatr Oncol* 1983;11:73-75.
- <sup>17</sup> Pendergrass TW. Congenital anomalies in children with Wilms' tumor: a new survey. *Cancer* 1976;37:403-409.
- <sup>18</sup> Breslow NE, Beckwith JB. Epidemiological features of Wilms' tumor: results of the National Wilms' Tumor Study. *J Natl Cancer Inst* 1982;68:429-436.
- <sup>19</sup> Brioude F, Kalish JM, Mussa A, et al. Expert consensus document: Clinical and molecular diagnosis, screening and management of Beckwith-Wiedemann syndrome: an international consensus statement. *Nat Rev Endocrinol* 2018;14:229-249.
- <sup>20</sup> Kalish JM, Doros L, Helman LJ, et al. Surveillance recommendation for children with overgrowth syndromes and predisposition to Wilms tumors and hepatoblastoma. *Clin Cancer Res* 2017;23:e115-e122.
- <sup>21</sup> Practice Committee of the American Society for Reproductive Medicine. Fertility preservation in patients undergoing gonadotoxic therapy or gonadectomy: a committee opinion. *Fertil Steril* 2019;112:1022-1033.
- <sup>22</sup> Lee SJ, Schover LR, Partridge AH, et al. American Society of Clinical Oncology recommendations on fertility preservation in cancer patients. *J Clin Oncol* 2006;24:2917-2931.

Version 2.2021, 06/17/21 © National Comprehensive Cancer Network, Inc. 2021. All rights reserved.  
The NCCN Guidelines® and this illustration may not be reproduced in any form without the express written permission of NCCN.

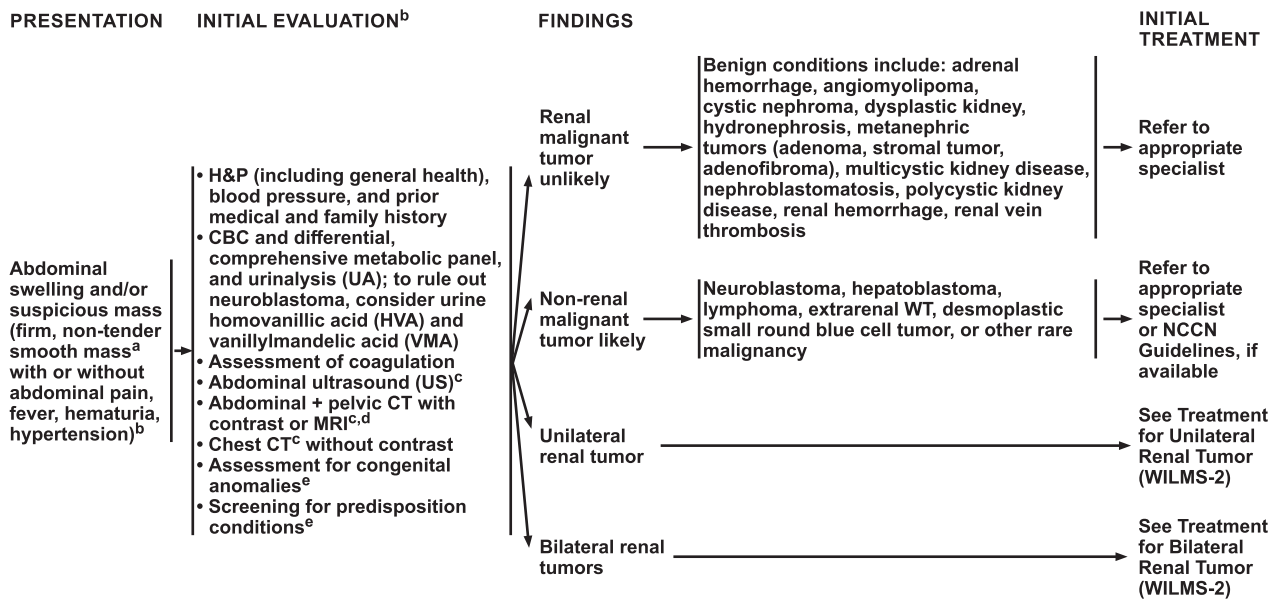
INTRO-1A

pain (37%), fever (23%), hematuria (21%–25%), and hypertension (20%–25%). Left-sided renal tumors can be confused on clinical examination with splenomegaly, and right-sided tumors with hepatomegaly. Less common symptoms include varicocele, hernia, enlarged testicle, congestive heart failure, hypoglycemia, Cushing syndrome, pleural effusion, acute abdomen, and acute rupture, bleeding, and shock. A healthy-appearing child is more likely to have WT, whereas an ill-appearing child with an abdominal mass may have neuroblastoma. Calcification of the tumor appears in approximately 5%–10% of WT, versus approximately 60%–70% of neuroblastomas. Almost 10% of patients with WT have coagulopathy (acquired von Willebrand disease).<sup>13</sup> WT can extend locally to perirenal soft tissues, renal vein, and vena cava. The most common sites of hematogenous metastases include lung (81%), lung and liver (15%), and other sites (4%); spread to regional lymph nodes also occurs.<sup>14</sup> However, WT rarely metastasizes to bone and brain, unlike clear cell sarcomas or other kidney cancers. Extrarenal tumors are a rare but well-recognized entity and usually are diagnosed by histology of a tumor occurring outside the kidney.

### Genetic Predisposition Conditions

Genetic conditions predisposing children to develop WT may be present in 10%–20% of cases.<sup>15,16</sup> Congenital anomalies such as aniridia, genitourinary abnormalities, gigantism, hemihyperplasia, macroglossia, or overgrowth may suggest the presence of certain genetic predisposition syndromes (see “Syndromes and Congenital Anomalies Associated with Wilms Tumor,” WILMS-I, in the algorithm). These genetic predisposition syndromes include Denys-Drash (associated with male pseudohermaphroditism, glomerulopathy), WAGR syndrome (WT, aniridia, genitourinary abnormalities, range of developmental delay), Beckwith-Wiedemann syndrome (associated with macroglossia, hemihyperplasia, gigantism, umbilical hernia), and other syndromes (see Syndromes and Congenital Anomalies Associated with Wilms Tumor [pages 970–972 in the algorithm]).<sup>15,17–35</sup> Genitourinary malformations (cryptorchidism, hypospadias, fused [horseshoe] kidneys) are found in 5% of children with WT; hemihyperplasia appears in 2%–3%.<sup>36,37</sup> Aniridia is present in 1% of children with WT.<sup>24,37,38</sup>

The most common germline variants involve *WT1*, which codes a transcription factor that is essential for normal kidney/genitourinary function.<sup>15,24,36–43</sup> *WT1* is a gene



<sup>e</sup> Conditions that predispose to the development of WT include genetic disorders such as Beckwith-Wiedemann, WAGR, Denys-Drash, Frasier, and Perlman syndromes; contralateral nephrogenic rests in children <12 months. Ten percent to 20% of WT occur in children with predisposing conditions. Children with known predisposing conditions should be screened for WT with physical exam (PE) and abdominal US every 3 months until at least 8 years of age. See Syndromes and Congenital Anomalies Associated with Wilms Tumor (WILMS-1). Consider germline testing for patients with physical findings consistent with a predisposition condition.

<sup>a</sup> Avoid vigorous or frequent palpation.  
<sup>b</sup> See Principles of Abdominal Mass Evaluation (WILMS-A).  
<sup>c</sup> See Principles of Imaging (WILMS-B).  
<sup>d</sup> CT with multiplanar reconstruction or MRI with contrast is recommended; MRI may be used when bilateral disease is suspected, as it may help to distinguish between nephrogenic rests and WT.

Version 2.2021, 06/17/21 © National Comprehensive Cancer Network, Inc. 2021. All rights reserved. The NCCN Guidelines® and this illustration may not be reproduced in any form without the express written permission of NCCN.

WILMS-1

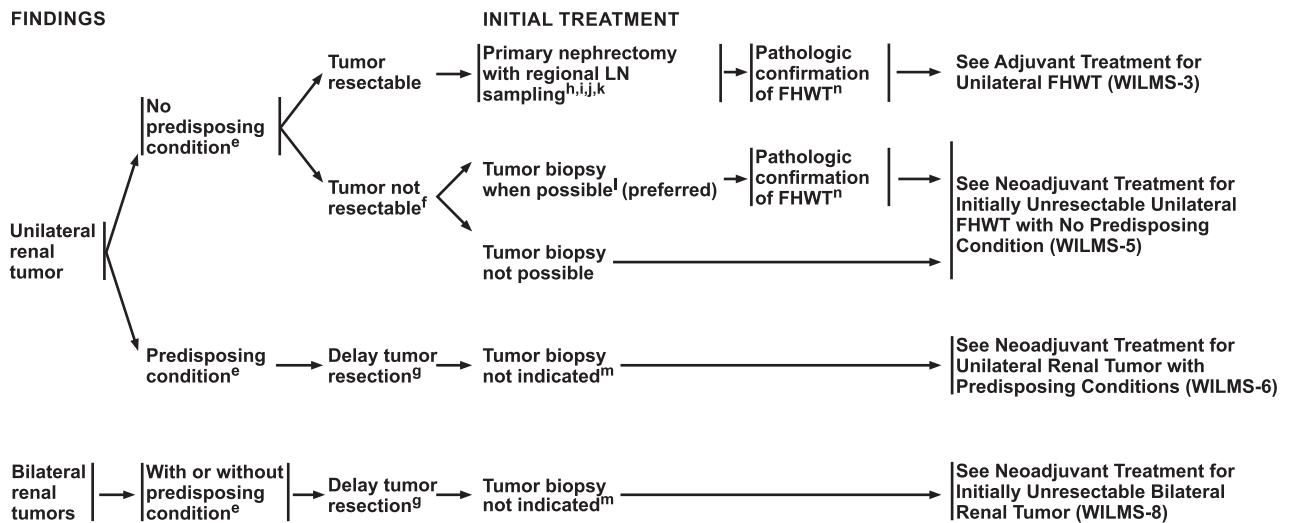
located within 11p13 and is found in WAGR syndrome, Denys-Drash syndrome, and Frasier syndrome, and is associated with bilateral WT. *WT2* is a gene located within 11p15 and results in overexpression of *IGF2*; it occurs in Beckwith-Wiedemann syndrome.

Numerous somatic genetic variants are associated with WT; the most common are *CTNNB1*, *DROSHA*, *WT1*, *WTX*, *WTX (AMER-1)*, *DGCR8*, *SIX1*, *BCORL1*, *MLL1*, *MYCN*, *SIX2*; *TP53* is associated with anaplastic WT. WT predisposition genes by exome sequencing include *REST*, *TRIM28*, *FBXW7*, *NYNRIN*, *KDM3B*, *XPO5*, *CHEK2*, and *PALB2*.<sup>44–46</sup> Familial WT gene mutations (*FWT1/FWT2*) are rare (1%–2% of WT) and are not associated with the *WT1* mutation. For children with WT, their siblings will rarely get WT (<1%). *FWT1* is on chromosome 17q; *FWT2* is on chromosome 19q.<sup>28,47–49</sup>

Children with genetic predisposition syndromes should receive routine screening for possible development of WT.<sup>16,50–53</sup> The goal is to identify and treat the WT at an early stage when the tumor is small and asymptomatic; this may hopefully be accomplished by partial nephrectomy, preserving renal tissue. It is important to note that the presence of a genetic predisposition syndrome does not mean that a child will develop WT. The different genetic

syndromes are associated with various levels of risk for WT. Children with Denys-Drash have approximately a 90% risk of developing WT; Perlman syndrome, approximately a 75% risk; and WAGR syndrome, approximately a 50% risk. Approximately 10% of children with Beckwith-Wiedemann syndrome will develop WT, but the risk varies with the genetic alteration. Children with Beckwith-Wiedemann syndrome who have germline hypermethylation of 11p15 have the highest risk (24%) of developing WT. Other syndromes with a greater than 1% risk include Simpson-Golabi-Behmel at 5%–10%; Mosaic Variegated Aneuploidy (BUB1B or TRIP13), >25%, and Bohring-Opitz (*ASXL1*) at 7%. Germline testing should be considered for children with physical findings consistent with a predisposition condition.

The American Association for Cancer Research recommends screening in all children with a greater than 1% risk of developing WT.<sup>16</sup> The NCCN Panel recommends that screening include physical examination and renal ultrasound every 3 months until children are at least 8 years of age based on the available data and clinical experience.<sup>16,51–53</sup> Children who present at a younger age are more likely to have multifocal/bilateral disease than children without a predisposition



<sup>e</sup> Conditions that predispose to the development of WT include genetic disorders such as Beckwith-Wiedemann, WAGR, Denys-Drash, Frasier, and Perlman syndromes; contralateral nephrogenic rests in children <12 months. Ten percent to 20% of WT occur in children with predisposing conditions. Children with known predisposing conditions should be screened for WT with PE and abdominal US every 3 months until at least 8 years of age. See Syndromes and Congenital Anomalies Associated with Wilms Tumor (WILMS-1). Consider germline testing for patients with physical findings consistent with a predisposition condition.

<sup>f</sup> Renal tumors may be unresectable at diagnosis because of tumor size, tumor thrombus extending above the hepatic veins, bilateral tumors, involvement of surrounding organs, or pulmonary function compromise from extensive metastatic disease.

<sup>g</sup> For tumors <2 cm, consider close surveillance given the challenge of differentiating WT from proliferating nephrogenic rests.

\*Available online, in these guidelines, at NCCN.org.

<sup>h</sup> Nephrectomy and regional LN sampling are recommended as initial therapy for resectable tumors. LN sampling **MUST** be performed for adequate staging; recommend obtaining minimum >5 (nodes) from areas in renal hilum anatomically expected to represent nodes associated with kidney.

<sup>i</sup> See Principles of Pathology (WILMS-C).

<sup>j</sup> See Principles of Surgery (WILMS-D).

<sup>k</sup> See COG Staging of Wilms Tumor (ST-1\*).

<sup>l</sup> Biopsy is recommended (preferred) for diagnosis and so that molecular biomarker testing can be done earlier and used for treatment decisions. See Principles of Biopsy (WILMS-E).

<sup>m</sup> Biopsy is not indicated for patients with bilateral Wilms and/or predisposing syndrome.

<sup>n</sup> Perform molecular analysis to identify loss of heterozygosity (LOH) of 1p, 16q, 11p, and 1q gain. If tumor is not WT, refer to appropriate specialist or NCCN Guidelines, if available. Other malignant renal tumors include clear cell sarcoma of the kidney, rhabdoid tumor, congenital mesoblastic nephroma, renal cell carcinoma, or renal medullary carcinoma.

Version 2.2021, 06/17/21 © National Comprehensive Cancer Network, Inc. 2021. All rights reserved. The NCCN Guidelines® and this illustration may not be reproduced in any form without the express written permission of NCCN.

WILMS-2

syndrome and often have been identified as part of a surveillance program.<sup>16,51</sup>

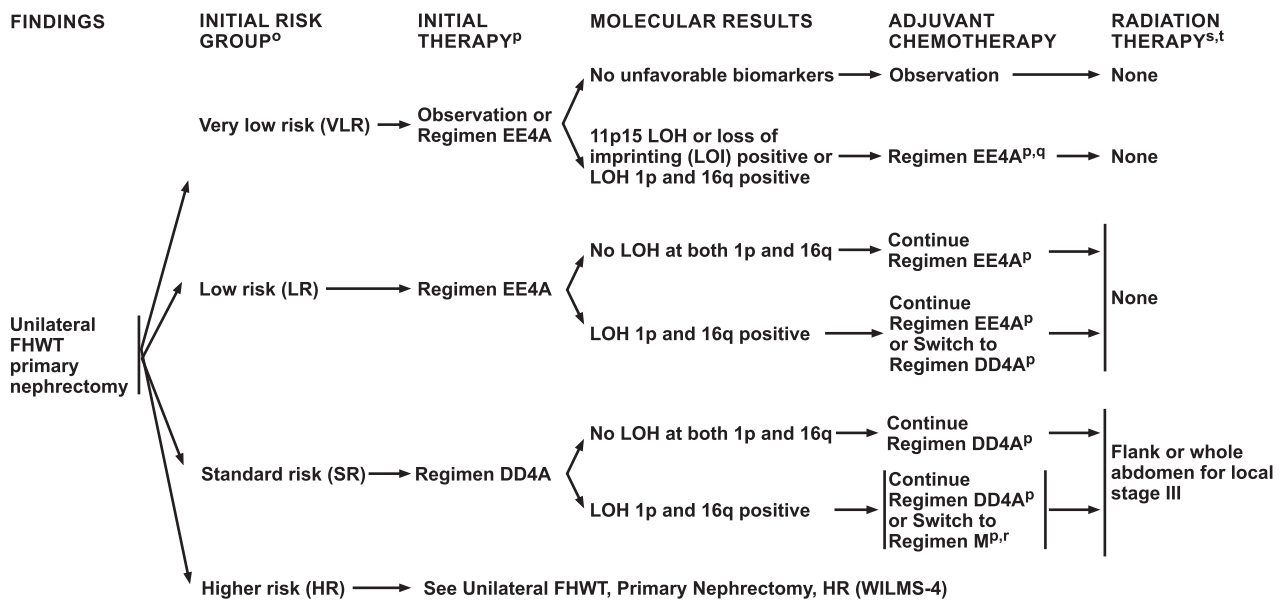
### Diagnosis

The differential diagnosis for children with abdominal swelling and/or a suspicious mass includes assessment for WT, renal tumors other than WT, extrarenal tumors, and benign renal conditions (see “Principles of Abdominal Mass Evaluation” [WILMS-A] in the algorithm). Initial testing recommended for children with a suspicious abdominal mass includes (1) history and physical examination, including blood pressure measurement along with assessment for genitourinary malformations (ie, cryptorchidism, hypospadias) and other congenital anomalies associated with WT; (2) blood chemistry tests, including renal function, liver function, complete blood count, and assessment of coagulation; and (3) imaging, including abdominal ultrasound and abdominal CT or MRI (see “Initial Evaluation” [WILMS-1] in the algorithm).

Abdominal ultrasound is typically the first imaging modality used, because it is usually easily obtained, can be performed without sedation, and can most often quickly ascertain both the presence of a mass and organ of origin.<sup>54,55</sup> Abdominal CT or MRI is then often used to

evaluate the extent and involvement of the renal mass identified on ultrasound.<sup>56,57</sup> Additional CT imaging of the pelvis may be indicated if the mass extends into the pelvis (see “Principles of Imaging” [WILMS-B] in the algorithm). The goal of imaging is to differentiate tumors of primary renal origin from extrarenal tumors and from benign renal conditions; imaging will also determine whether a child has unilateral or bilateral kidney disease and whether metastatic disease is present (see “Principles of Imaging” [WILMS-B] in the algorithm). It is also important to assess for ascites, which may raise concern for tumor rupture.

If a diagnosis of WT or any malignant renal tumor is suspected, assessment for metastatic disease should be performed. Chest CT should be done to evaluate for pulmonary nodules, which is the most common site of metastatic disease. It is always preferable to perform a chest CT unsedated, and before any other sedation, to avoid the complication of atelectasis complicating the evaluation. If the organ of origin of the abdominal mass is not clear, then additional testing should be considered, such as urine catecholamines, alpha-fetoprotein, or beta-human chorionic gonadotropin. Surgery is recommended for most children with suspected unilateral WT at diagnosis. Although a



<sup>o</sup> Initial Risk Group based on histology, stage, age, and tumor weight. See Risk Assessment for FHWT (WILMS-F).  
<sup>p</sup> See Principles of Chemotherapy for FHWT (WILMS-G).  
<sup>q</sup> A retrospective analysis of the biology suggests patients with VLR FHWT and 11p15 LOH or LOI may not be suitable for reduction of therapy (observation without adjuvant chemotherapy).

<sup>r</sup> Regimen M has a greater risk of increased toxicity and late effects, including second cancers and infertility related to cyclophosphamide and etoposide. There are issues with the historical comparison group that has been used to justify augmenting therapy with Regimen M.  
<sup>s</sup> See Principles of Radiation Therapy for FHWT (WILMS-H).  
<sup>t</sup> RT is often given 10 to 14 days after surgery. However, consider patient factors when deciding about the timing of RT (eg, age of patient, need to assess response of lung metastases to chemotherapy, when giving whole abdomen and whole lung RT). Local stage III refers to staging at the primary tumor regardless of metastases.

Version 2.2021, 06/17/21 © National Comprehensive Cancer Network, Inc. 2021. All rights reserved. The NCCN Guidelines® and this illustration may not be reproduced in any form without the express written permission of NCCN.

WILMS-3

clinical stage is determined before surgery, confirming the diagnosis of WT and complete staging occurs after surgery. The surgical tissue is used for complete pathologic evaluation, to assess histology, and to measure molecular markers; this information is used to determine the most appropriate postoperative treatment regimens.

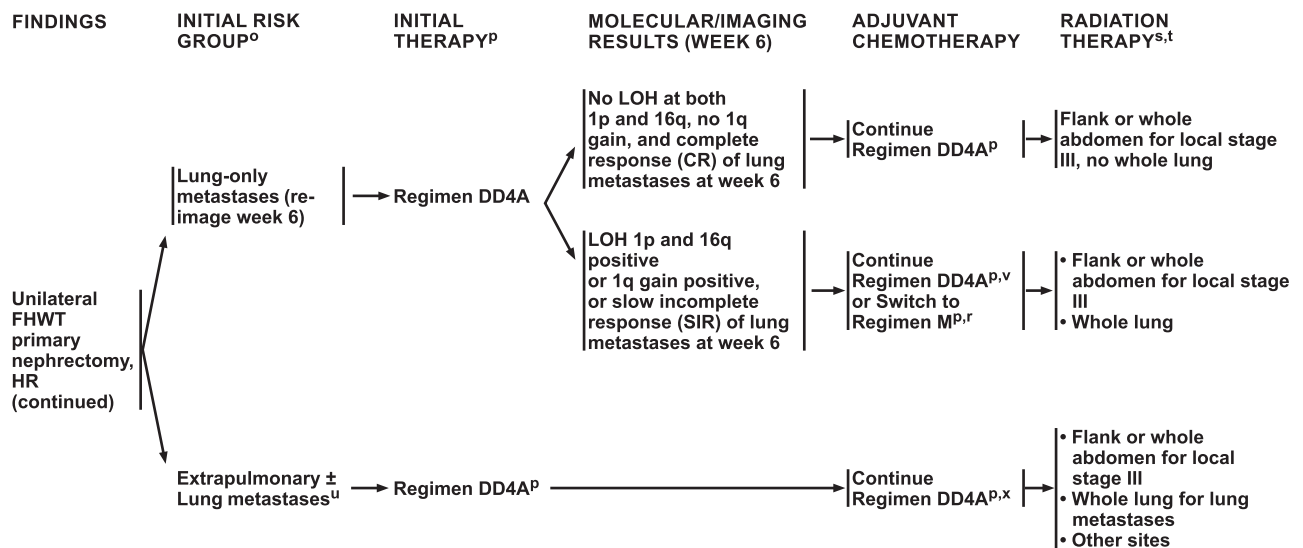
Renal tumors other than WT include clear cell sarcoma of the kidney, congenital mesoblastic nephroma, renal cell carcinoma (including renal medullary carcinoma), rhabdoid tumor of the kidney, renal sarcoma, primitive neuroectodermal tumors, DICER1-associated sarcoma, desmoplastic small round cell tumors, renal neuroblastoma, and perivascular epithelioid cell tumors. Other intrabdominal malignancies that would produce a flank mass include Burkitt lymphoma, desmoplastic small round cell tumors, Ewing sarcoma, extrarenal WT, hepatoblastoma, neuroblastoma, rhabdomyosarcoma, malignant germ cell tumors, or other rare malignancies. Patients with nephroblastomatosis are at risk for WT development and those with cystic nephroma are at risk for transformation to renal sarcoma. Benign renal conditions need to be ruled out, including adrenal hemorrhage, angiomyolipoma, dysplastic kidney, hydronephrosis, metanephric tumors (ie, adenoma, stromal tumor,

adenofibroma), multicystic kidney disease, polycystic kidney disease, renal hemorrhage, and renal vein thrombosis.

### Pathology

To avoid potential tumor spread from malignant tumors, biopsy is not routinely recommended before upfront surgery. If the patient has a resectable unilateral renal tumor (outside the setting of known WT predisposition syndromes), upfront nephrectomy is recommended when feasible (see “Treatment of Unilateral Renal Tumor” [WILMS-2] and “Principles of Biopsy” [WILMS-E] in the algorithm). A biopsy to establish a pathologic diagnosis is strongly recommended for children with a unilateral, initially unresectable renal tumor but without a predisposing condition. For children with a biopsy showing FHWT, molecular testing on diagnostic tissue is also required to stratify therapy. Fine-needle aspiration is never recommended. Either core needle biopsies guided by interventional radiology or open biopsy can be considered.

Initiation of therapy without biopsy is the recommended approach for the subset of patients younger than 10 years with bilateral renal tumors, or patients with known predisposition syndromes and unilateral or bilateral renal tumors, because the likelihood of those tumors



<sup>o</sup> Initial Risk Group based on histology, stage, age, and tumor weight. See Risk Assessment for FHWT (WILMS-F).  
<sup>p</sup> See Principles of Chemotherapy for FHWT (WILMS-G).  
<sup>r</sup> Regimen M has a greater risk of increased toxicity and late effects, including second cancers and infertility related to cyclophosphamide and etoposide. There are issues with the historical comparison group that has been used to justify augmenting therapy with Regimen M.  
<sup>s</sup> See Principles of Radiation Therapy for FHWT (WILMS-H).

<sup>t</sup> RT is often given 10 to 14 days after surgery. However, consider patient factors when deciding about the timing of RT (eg, age of patient, need to assess response of lung metastases to chemotherapy, when giving whole abdomen and whole lung RT). Local stage III refers to staging of the primary tumor regardless of metastases.  
<sup>u</sup> If feasible, resect metastatic tumors at the time of primary nephrectomy.  
<sup>v</sup> Patients with 1q gain, no LOH, and CR of lung metastases at week 6 should continue on Regimen DD4A but should have whole lung irradiation (WLI). Omission of WLI for patients with CR of lung metastases at week 6 and 1q gain is not recommended because of lower event-free survival (EFS; 57%). Intensification of therapy for this group has not been studied.  
<sup>x</sup> Patients with extrapulmonary metastases were switched to Regimen M on AREN0533, but results have not been published.

Version 2.2021, 06/17/21 © National Comprehensive Cancer Network, Inc. 2021. All rights reserved. The NCCN Guidelines® and this illustration may not be reproduced in any form without the express written permission of NCCN.

WILMS-4

representing WT is so high (and a secondary goal of therapy is to spare renal parenchyma). However, biopsy is recommended to confirm the diagnosis of FHWT (or WT without evidence of anaplasia) if a less than partial response to neoadjuvant chemotherapy is determined at week 6, especially if a biopsy was not performed at initial presentation.

Information that can be obtained through biopsy is limited. A diagnosis of FHWT obtained on a biopsy implies that focal or diffuse anaplasia is absent (see “Principles of Pathology” [WILMS-C] in the algorithm). It is important to know that anaplastic histology is often not identified in patients who had core needle or open wedge resection biopsy; however, anaplastic histology is identified when using tissue specimens from nephrectomy.<sup>58</sup> As previously mentioned, these NCCN Guidelines only address FHWT at this time; anaplastic histology is less common.

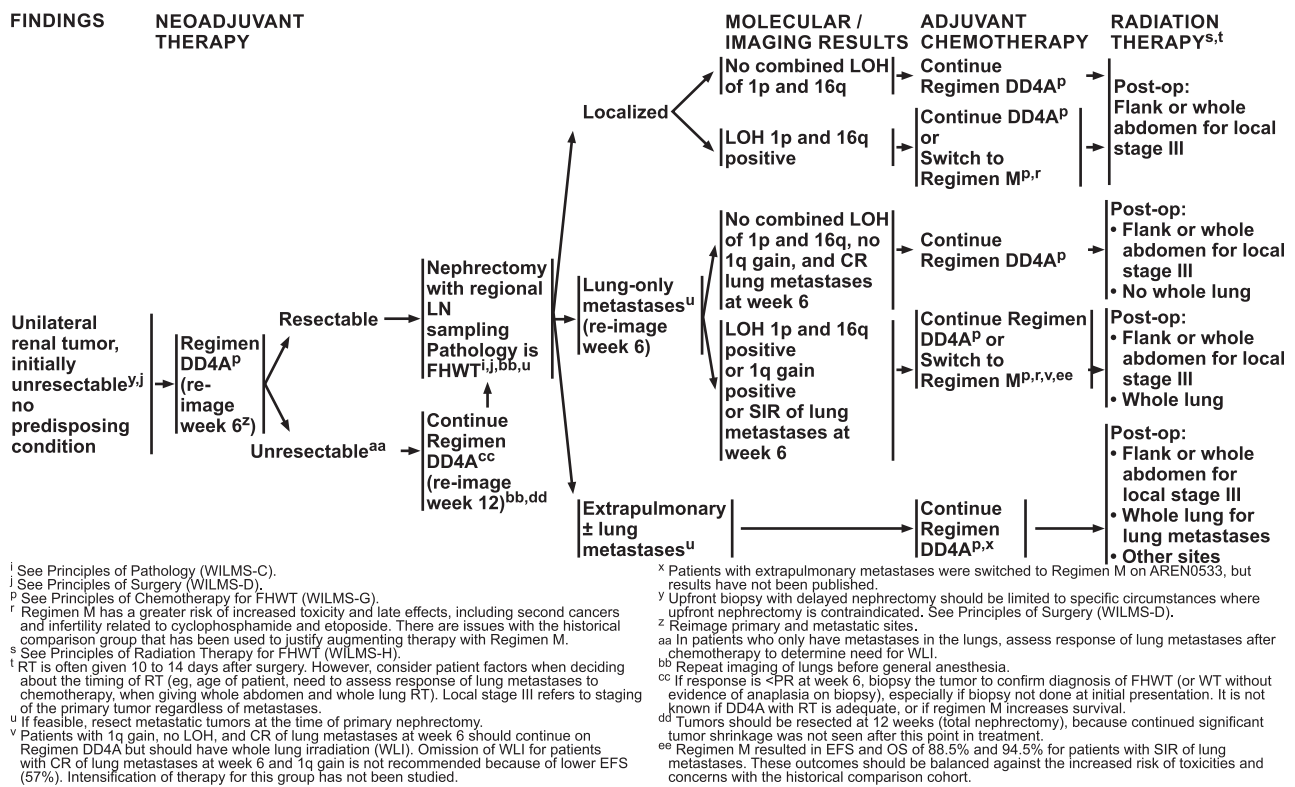
Biopsies are also limited in distinguishing nephrogenic rests from WT. Nephrogenic rests are benign foci of embryonal kidney cells; they are precursors of WT. Hyperplastic nephrogenic rests are premalignant WT.<sup>39,59,60</sup> Unless a rim of capsule or normal tissue is included in the sample, a core or needle biopsy cannot distinguish between nephrogenic rests and WT. In patients with small

lesions suspicious for bilateral WT, it is difficult to distinguish nephrogenic rests from WT using imaging and percutaneous biopsies; MRI may be useful in this setting.<sup>61</sup>

### Staging

WTs are staged both locally (reflecting abdominal spread of the tumor) and overall. Patients with any evidence of metastatic disease (most commonly lungs and liver) seen on imaging are staged as overall stage IV. Abdominal staging can be stage I (limited to renal parenchyma); stage II, demonstrating invasion into renal pelvis or renal capsule; or stage III (with tumor outside the capsule, remaining in the abdomen, including finding of positive margins, confirmation of preoperative or intraoperative tumor spill or rupture, positive lymph nodes, or tumor without upfront resection; see “Children’s Oncology Group (COG) Staging System of Wilms Tumor,” ST-1, available in this algorithm at NCCN.org]. Staging is critical to overall risk stratification and therapy assignment, for both chemotherapy and RT.

The stage of renal disease is determined mainly by findings at surgery; imaging is useful but may overstage or understage patients.<sup>54–56,62</sup> In North America, the Children’s Oncology Group (COG) staging system for WT is used (see ST-1, in the algorithm at NCCN.org). Lymph node



Version 2.2021, 06/17/21 © National Comprehensive Cancer Network, Inc. 2021. All rights reserved. The NCCN Guidelines® and this illustration may not be reproduced in any form without the express written permission of NCCN.

WILMS-5

sampling is recommended in patients with resectable tumors to accurately stage the tumor (see “Principles of Surgery” [WILMS-D] in the algorithm).<sup>63</sup> Local stage refers to the staging of the primary tumor, regardless of metastases (eg, stage IV with local stage III) and is used to determine the need for flank RT or whole abdominal irradiation (WAI) (see “Principles of Radiation Therapy for FHWT” [WILMS-H] in the algorithm).<sup>62</sup>

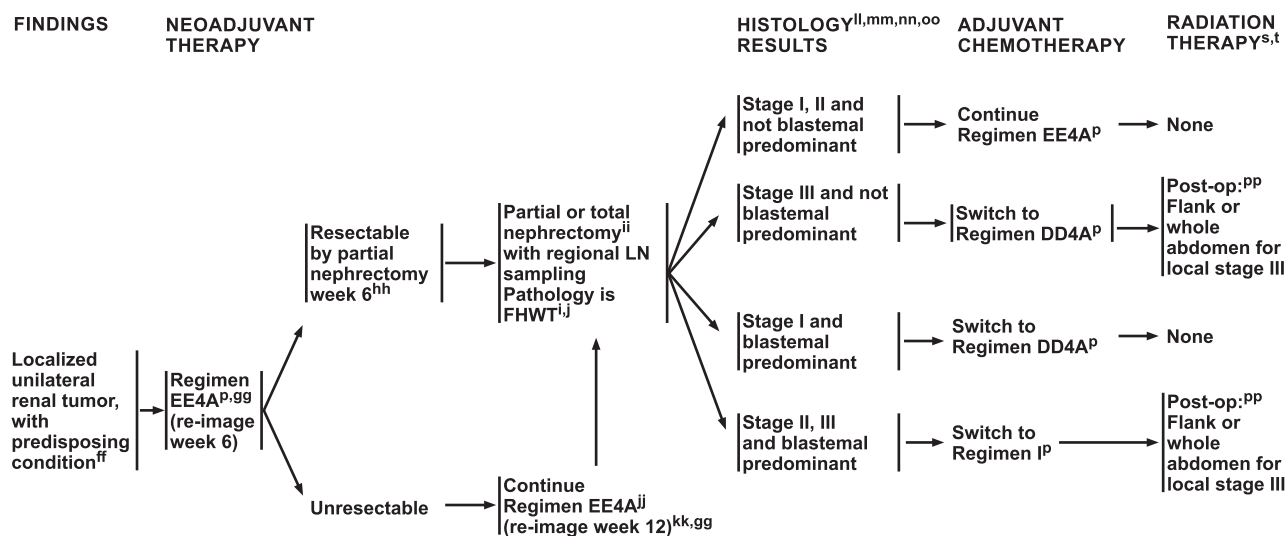
### Treatment Overview

Treatment of WT ranges from surgery only to intensive chemotherapy, surgery, and RT, depending on whether the WT is unilateral or bilateral, local stage, presence of metastases, patient’s age, tumor weight, biologic risk factors, histology, and clinical response to therapy. A multidisciplinary evaluation with surgeons, pediatric oncologists, and radiation oncologists is recommended before treatment. Surgery is recommended at some point for most children with suspected WT, including those who are initially unresectable, or those with bilateral or metastatic disease. Risk assessment is done to determine the need for and type of adjuvant therapy after surgery (see Risk Assessment for FHWT [WILMS-F] in the algorithm).<sup>10,64</sup> Most children have resectable unilateral kidney disease, and

upfront unilateral nephrectomy is recommended for these children (see “Initial Treatment of Unilateral Renal Tumor” [WILMS-2] in the algorithm). Multifocal unilateral (10%) or primary bilateral renal tumors (5%–13%) are less common.

The goals of treatment are to maximize cure while appropriately risk stratifying patients to minimize long-term toxicity of therapy by selecting less-intensive treatment if possible. Long-term toxicity includes risk of secondary malignancy from chemotherapy and/or RT and development of end-stage renal disease among other long-term risks of surgery and RT. In cancer survivorship cohorts, with patients surviving many decades after diagnosis of WT, it has been shown that patients treated with historic regimens have an increased incidence (65%) of chronic health problems, 25 years after treatment; the incidence of severe conditions was 24%.<sup>65</sup> The risk of long-term renal failure after treatment is only 0.6% in most patients with unilateral FHWT.<sup>20</sup> The incidence of end-stage renal disease is higher (12%) in children with bilateral WT.<sup>20</sup> Other risk factors for end-stage renal failure include radiation and congenital syndromes (eg, Denys-Drash, WAGR). Patients treated with RT have an increased risk for second malignancies.<sup>66–68</sup>





<sup>i</sup> See Principles of Pathology (WILMS-C).  
<sup>j</sup> See Principles of Surgery (WILMS-D).  
<sup>k</sup> See Principles of Chemotherapy for FHWT (WILMS-G).  
<sup>l</sup> See Principles of Radiation Therapy for FHWT (WILMS-H).  
<sup>m</sup> RT is often given 10 to 14 days after surgery. However, consider patient factors when deciding about the timing of RT (eg, age of patient, need to assess response of lung metastases to chemotherapy, when giving whole abdomen and whole lung RT). Local stage III refers to staging of the primary tumor regardless of metastases.  
<sup>n</sup> Upfront biopsy or resection is discouraged.  
<sup>o</sup> Switch to Regimen VAD if biopsy was performed up front.  
<sup>p</sup> No surgery if there is a CR on reimaging.  
<sup>q</sup> AREN0534 specified a total nephrectomy for less than a PR at week 6.  
<sup>r</sup> If response is <PR at week 6, biopsy the tumor to confirm diagnosis of FHWT (or WT without evidence of anaplasia on biopsy), especially if biopsy not done at initial presentation.

<sup>kk</sup> Tumors should be resected at week 12 (partial or total nephrectomy), because continued significant tumor shrinkage was not seen after that point in treatment.  
<sup>ll</sup> Molecular biomarkers were not used to direct therapy.  
<sup>mm</sup> Use of biomarkers from post-chemotherapy tumor has not been established to correlate with outcome, nor has it been used to direct therapy in prospective trial. Outcomes on AREN0534 were excellent despite this. Regimen M not studied in this population.  
<sup>nn</sup> Neoadjuvant chemotherapy is not a criterion for upstaging to stage III in this population.  
<sup>oo</sup> If biopsied, a tumor is considered to be stage III for determination of chemotherapy regimen, but biopsy alone does not upstage a tumor to stage III for determining whether to give radiation.  
<sup>pp</sup> See ST-1<sup>7</sup> for staging criteria.

\*Available online, in these guidelines, at NCCN.org.

Version 2.2021, 06/17/21 © National Comprehensive Cancer Network, Inc. 2021. All rights reserved. The NCCN Guidelines® and this illustration may not be reproduced in any form without the express written permission of NCCN.

WILMS-6

### Neoadjuvant Chemotherapy

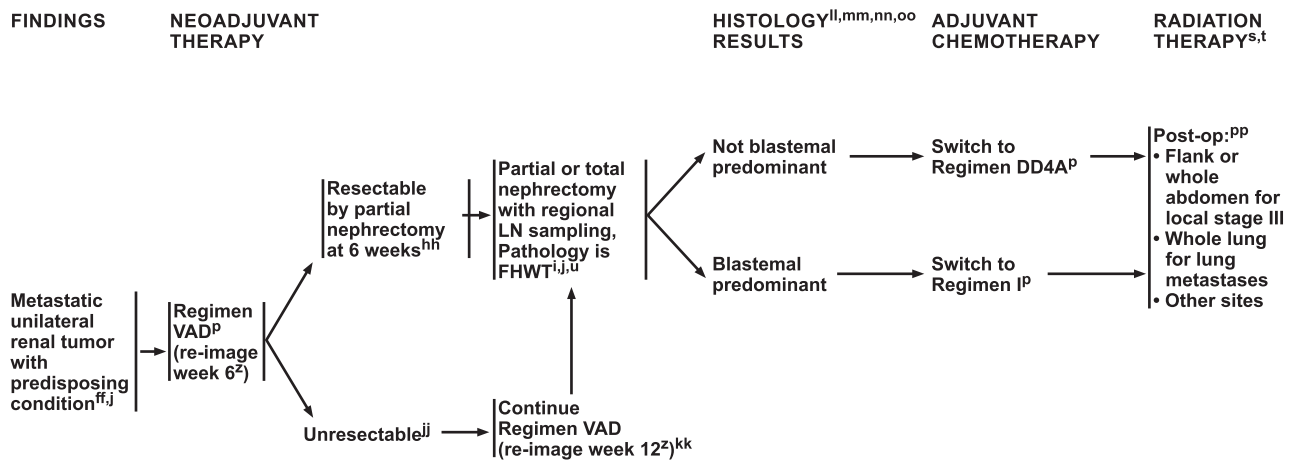
Neoadjuvant chemotherapy is recommended to shrink the tumors before surgery in children with bilateral WT, those with initially unresectable unilateral tumors, or those with predisposing conditions and either localized or metastatic unilateral renal tumors.<sup>69,70</sup> Specific chemotherapy regimens are given for 6 weeks and then the tumor response is assessed (see “Principles of Chemotherapy” [WILMS-G] in the algorithm). Details are provided regarding neoadjuvant chemotherapy and regimens that are recommended for specific settings (see “Chemotherapy” [page 955] and “Neoadjuvant Chemotherapy” [page 956] in this Discussion).

### Surgery

The surgical goals for WT include removal of all disease without rupturing the tumor(s) (ie, no gross tumor spill), accurate lymph node staging, and complete pathologic evaluation.<sup>71</sup> Most patients with FHWT will have unilateral radical ureteronephrectomy. Surgery must include regional lymph node sampling.<sup>72–76</sup> Nephron-sparing surgery (NSS) is reserved for patients with bilateral disease, those who are genetically predisposed, or those at other higher risk for renal failure.<sup>73,77–79</sup> NSS is not recommended

for unilateral disease if there is no genetic predisposition. In addition, testing is done on the surgical tissue specimens to confirm the diagnosis, assess for certain molecular markers (eg, loss of heterozygosity [LOH]), and to determine histology (eg, blastemal predominant, anaplasia); the results are used for risk stratification to select the appropriate adjuvant therapy.

Before treatment, it is essential to determine whether the tumor is resectable, the appropriate type and timing of surgery, and whether neoadjuvant chemotherapy is needed to shrink tumors before surgery (see “Principles of Surgery” [WILMS-D] in the algorithm). Although a clinical stage is determined before surgery, confirming the diagnosis of WT and complete staging occur after surgery. The evaluation of resectability includes assessment of the following: number and extent of tumors; and whether the patient is at risk for pulmonary compromise, tumor spill, or long-term renal failure. Contraindications to upfront surgery include tumor extension to contiguous structures; solitary kidney; extension of tumor thrombus above the hepatic veins; unacceptable anesthesia risk due to pulmonary metastases or very large abdominal tumors; and/or risk for significant morbidity or mortality, gross tumor spill, residual tumor, or long-term renal



<sup>i</sup> See Principles of Pathology (WILMS-C).  
<sup>j</sup> See Principles of Surgery (WILMS-D).  
<sup>p</sup> See Principles of Chemotherapy for FHWT (WILMS-G).  
<sup>s</sup> See Principles of Radiation Therapy for FHWT (WILMS-H).  
<sup>t</sup> RT is often given 10 to 14 days after surgery. However, consider patient factors when deciding about the timing of RT (eg, age of patient, need to assess response of lung metastases to chemotherapy, when giving whole abdomen and whole lung RT). Local stage III refers to staging of the primary tumor regardless of metastases.  
<sup>u</sup> If feasible, resect metastatic tumors at the time of primary nephrectomy.  
<sup>z</sup> Reimage primary and metastatic sites.  
<sup>ff</sup> Upfront biopsy or resection is discouraged.  
<sup>hh</sup> No surgery if there is a CR on reimaging.  
<sup>jj</sup> If response is <PR at week 6, biopsy the tumor to confirm diagnosis of FHWT (or WT without evidence of anaplasia on biopsy), especially if biopsy not done at initial presentation.  
 \*Available online, in these guidelines, at NCCN.org.

<sup>kk</sup> Tumors should be resected at week 12 (partial or total nephrectomy), because continued significant tumor shrinkage was not seen after that point in treatment.  
<sup>ll</sup> Molecular biomarkers were not used to direct therapy.  
<sup>mmm</sup> Use of biomarkers from post-chemotherapy tumor has not been established to correlate with outcome, nor has it been used to direct therapy in prospective trial. Outcomes on AREN0534 were excellent despite this. Regimen M not studied in this population.  
<sup>nn</sup> Neoadjuvant chemotherapy is not a criterion for upstaging to stage III in this population. Response of lung metastases at week 6 to determine whether WL1 could be omitted has not been studied in this population.  
<sup>oo</sup> If biopsied, a tumor is considered to be stage III for determination of chemotherapy regimen, but biopsy alone does not upstage a tumor to stage III for determining whether to give radiation.  
<sup>pp</sup> See ST-1\* for staging criteria.

Version 2.2021, 06/17/21 © National Comprehensive Cancer Network, Inc. 2021. All rights reserved. The NCCN Guidelines® and this illustration may not be reproduced in any form without the express written permission of NCCN.

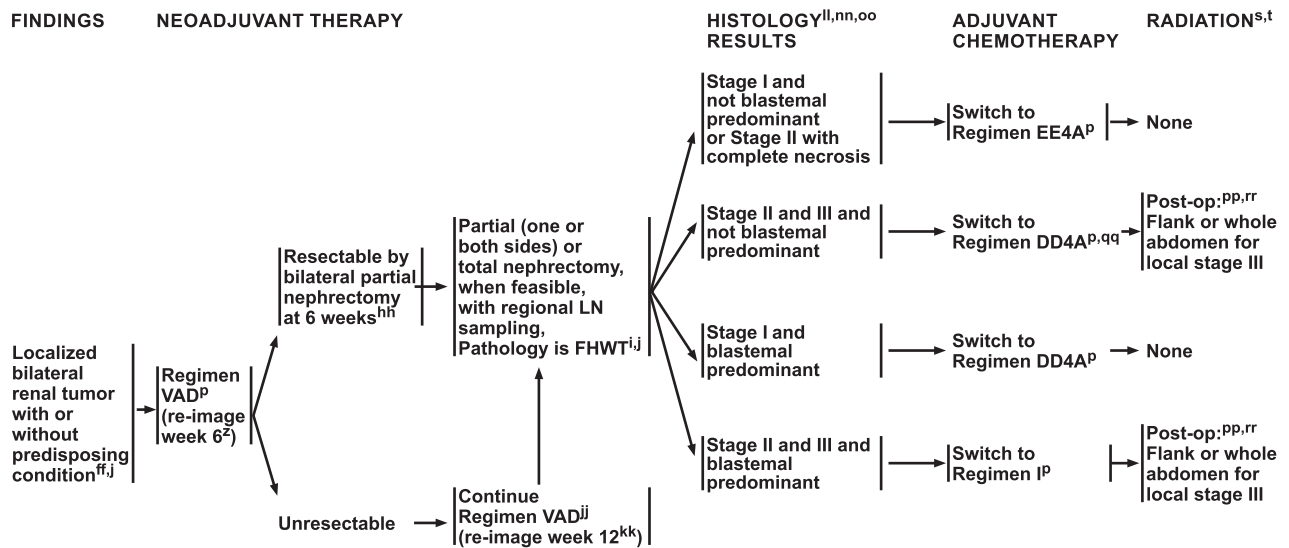
WILMS-7

failure.<sup>80</sup> Metastases are not typically a contradiction to surgery.

The preferred surgical approaches are transabdominal or thoracoabdominal exposure with transperitoneal approach to avoid tumor spillage.<sup>76,81–83</sup> Surgery includes assessment of size and extent of the tumor(s); abdominal exploration; lymph node sampling (minimum of 5 nodes from the renal hilum that are associated with the kidney, paracaval, and para-aortic regions is recommended); and assessment for tumor rupture, ascites, and retroperitoneal adenopathy (see “Principles of Surgery” [WILMS-D] in the algorithm).<sup>63,72,84,85</sup> WT rarely invades surrounding organs although it frequently adheres to them; en-bloc resection of surrounding organs is not needed. The adrenal gland only needs to be removed if there is tumor involvement.<sup>86</sup> Although abdominal CT or MRI is recommended before surgery, imaging cannot replace surgical exploration. Any tumor spillage must be documented to guide therapy.<sup>87</sup> Patients with spillage are classified as stage III and RT is recommended. Minimally invasive surgery is not recommended for children with WT at this time. Depending on the setting and response to neoadjuvant chemotherapy, nephrectomy (partial [one or both sides] or total) is done; surgery must include regional lymph node sampling.<sup>72–76</sup>

### Risk-Based Assessment

Risk stratification is used to determine the most appropriate therapy to minimize both risk of recurrence and long-term toxicity from treatment.<sup>64,65,88</sup> Tumor histology, histopathologic and surgical stage, molecular markers (LOH of 1p and 16q), presence of metastatic and/or bilateral disease, and clinical factors, including age of the child, presence or absence of predisposition syndromes, and response of pulmonary lesions to neoadjuvant chemotherapy, are all used in risk stratification (see “Initial and Final Risk Assessment for Favorable Histology Wilms Tumor” [WILMS-F] in the algorithm). Risk stratification has evolved using data from large collaborative clinical trials. The presence of specific molecular biomarkers—such as LOH of 1p and 16q, 11p15, and 1q gain—identified in tumor tissue is associated with increased risk of relapse after initial therapy. Cytogenetic and molecular testing—for 1q gain and/or LOH of 1p and 16q—is recommended for all children with newly diagnosed FHWT.<sup>8,89,90</sup> Other molecular markers may be reported after testing; however, at this time, data do not support the use of other markers for risk stratification. The use of specific molecular markers for risk-based assessment is evolving based on clinical trial data.



<sup>i</sup> See Principles of Pathology (WILMS-C).  
<sup>j</sup> See Principles of Surgery (WILMS-D).  
<sup>k</sup> See Principles of Chemotherapy for FHWT (WILMS-G).  
<sup>l</sup> See Principles of Radiation Therapy for FHWT (WILMS-H).  
<sup>m</sup> RT is often given 10 to 14 days after surgery. However, consider patient factors when deciding about the timing of RT (eg, age of patient, need to assess response of lung metastases to chemotherapy, when giving whole abdomen and whole lung RT). Local stage III refers to staging of the primary tumor regardless of metastases.  
<sup>n</sup> Reimage primary and metastatic sites.  
<sup>o</sup> Upfront biopsy or resection is discouraged.  
<sup>p</sup> No surgery if there is a CR on reimaging.

<sup>q</sup> If response is <PR at week 6, biopsy the tumor to confirm diagnosis of FHWT (or WT without evidence of anaplasia on biopsy), especially if biopsy not done at initial presentation.  
<sup>r</sup> Tumors should be resected at week 12 (partial or total nephrectomy), because continued significant tumor shrinkage was not seen after that point in treatment.  
<sup>s</sup> Molecular biomarkers were not used to direct therapy.  
<sup>t</sup> Neoadjuvant chemotherapy is not a criterion for upstaging to stage III in this population.  
<sup>u</sup> If biopsied, a tumor is considered to be stage III for determination of chemotherapy regimen, but biopsy alone does not upstage a tumor to stage III for determining whether to give radiation.  
<sup>v</sup> See ST-1\* for staging criteria.  
<sup>w</sup> Stage II with complete necrosis can switch to Regimen EE4A.  
<sup>x</sup> Stage III that is upstaged because of biopsy alone will not receive RT.

\*Available online, in these guidelines, at NCCN.org.

Version 2.2021, 06/17/21 © National Comprehensive Cancer Network, Inc. 2021. All rights reserved. The NCCN Guidelines® and this illustration may not be reproduced in any form without the express written permission of NCCN.

WILMS-8

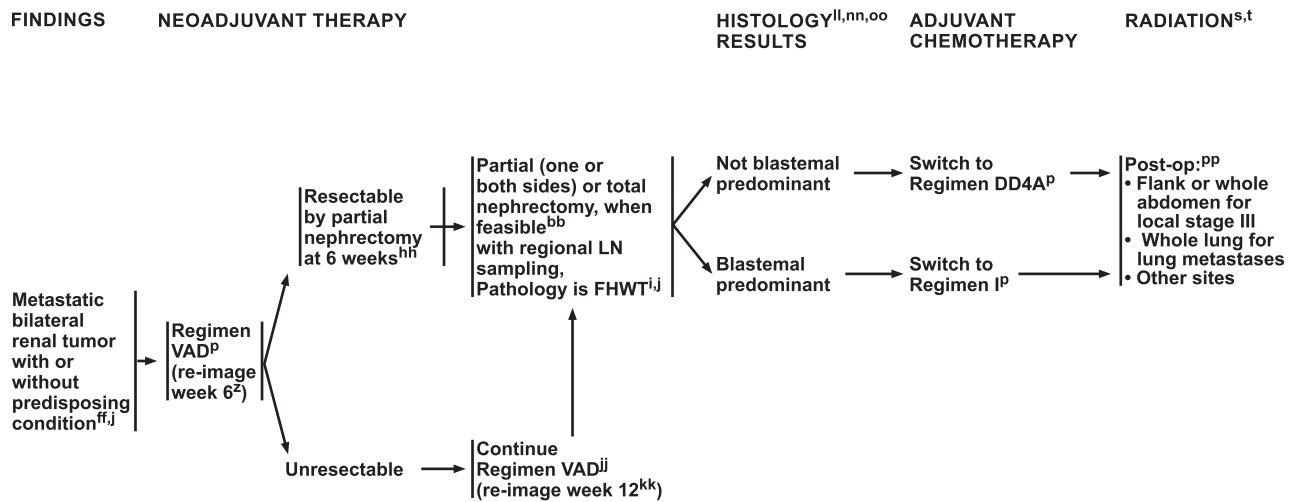
Several segmental chromosomal aberrations correlate with increased risk, including LOH of 1p and 16q, gain of 1q, and LOH and LOI of 11p15. To date, only alteration of therapy for combined LOH of 1p and 16 has been studied in a prospective clinical trial. However, the presence of certain unfavorable biomarkers clearly identifies children with potential increased risk when treated with therapy deintensification (patients classified with very-low-risk WT found to have LOH of 11p15, or patients with stage IV disease and rapid complete response of pulmonary metastases found to have 1q gain). Therefore, clinicians should consider assessing for all of these biomarkers in all children with FHWT.

Initial risk assessment is based on age and clinical, radiographic, surgical, and pathologic findings. Final risk assessment is based on the initial risk factors plus presence or absence of unfavorable molecular biomarkers and the response of the lung metastases at week 6, if applicable. Factors indicating need for more intensive therapy include: older age at diagnosis, unfavorable/anaplastic histology, higher stage, larger tumor weight, unfavorable molecular biomarkers, and incomplete lung nodule response to neoadjuvant chemotherapy at week 6. Excellent outcomes have

been achieved for all stages of FHWT, including those patients with higher stage disease, unfavorable biomarkers, and adverse clinical factors, such as incomplete lung response; these patients are stratified to more intensive therapy with additional chemotherapy agents and RT.

**Chemotherapy**

Data show that neoadjuvant and/or adjuvant chemotherapy in combination with surgery (with or without RT) improves survival for most children with WT.<sup>11,61,91,92</sup> Chemotherapy regimens include (1) EE4A (vincristine and dactinomycin); (2) DD4A (vincristine, dactinomycin, and doxorubicin); (3) VAD (vincristine, dactinomycin, and doxorubicin); (4) regimen M (vincristine, dactinomycin, doxorubicin, cyclophosphamide, and etoposide); and (5) regimen I (vincristine, doxorubicin, cyclophosphamide, and etoposide) (see “Principles of Chemotherapy” [WILMS-G] in the algorithm). Although many of the same agents are used in the different regimens, the schedule varies. Some of the chemotherapy regimens may be used for neoadjuvant or adjuvant chemotherapy. In the National Wilms Tumor Study (NWTs), chemotherapy was first given at week 0; however, COG chemotherapy



<sup>i</sup> See Principles of Pathology (WILMS-C).  
<sup>j</sup> See Principles of Surgery (WILMS-D).  
<sup>p</sup> See Principles of Chemotherapy for FHWT (WILMS-G).  
<sup>s</sup> See Principles of Radiation Therapy for FHWT (WILMS-H).  
<sup>t</sup> RT is often given 10 to 14 days after surgery. However, consider patient factors when deciding about the timing of RT (eg, age of patient, need to assess response of lung metastases to chemotherapy, when giving whole abdomen and whole lung RT). Local stage III refers to staging of the primary tumor regardless of metastases.  
<sup>z</sup> Reimage primary and metastatic sites.  
<sup>bb</sup> Reimage primary and metastatic sites. Repeat imaging of lungs before general anesthesia.  
<sup>ff</sup> Upfront biopsy or resection is discouraged.

<sup>hh</sup> No surgery if there is a CR on reimaging.  
<sup>jj</sup> If response is <PR at week 6, biopsy the tumor to confirm diagnosis of FHWT (or WT without evidence of anaplasia on biopsy), especially if biopsy not done at initial presentation.  
<sup>kk</sup> Tumors should be resected at week 12 (partial or total nephrectomy), because continued significant tumor shrinkage was not seen after that point in treatment.  
<sup>ll</sup> Molecular biomarkers were not used to direct therapy.  
<sup>nn</sup> Neoadjuvant chemotherapy is not a criterion for upstaging to stage III in this population.  
<sup>oo</sup> If biopsied, a tumor is considered to be stage III for determination of chemotherapy regimen, but biopsy alone does not upstage a tumor to stage III for determining whether to give radiation.  
<sup>pp</sup> See ST-1\* for staging criteria.

Version 2.2021, 06/17/21 © National Comprehensive Cancer Network, Inc. 2021. All rights reserved. The NCCN Guidelines® and this illustration may not be reproduced in any form without the express written permission of NCCN.

WILMS-9

starts at week 1. The number of doses of chemotherapy is the same.

In the EE4A regimen, 13 doses of vincristine and 7 doses of dactinomycin are administered over 18 weeks.<sup>91,93</sup> In the DD4A regimen, 15 doses of vincristine (10 weekly, 5 every 3 weeks), 5 doses of dactinomycin, and 4 doses of doxorubicin (cumulative dose 150 mg/m<sup>2</sup>) are administered over 24 weeks with alternating doses of dactinomycin and doxorubicin every 3 weeks.<sup>91,93</sup> In the VAD regimen, 6 to 12 doses of vincristine, 2 to 4 doses of dactinomycin, and 2 to 4 doses of doxorubicin (cumulative dose 70–140 mg/m<sup>2</sup>) are administered over 6 to 12 weeks based on treatment response and timing of surgery; this regimen is only used in the neoadjuvant setting for patients who are candidates for NSS.<sup>61</sup> In the VAD regimen, dactinomycin and doxorubicin are given together. Regimen M consists of 9 doses of vincristine, 5 doses of dactinomycin, 5 doses of doxorubicin (cumulative dose 150 mg/m<sup>2</sup>), 4 courses of 5 daily doses of cyclophosphamide, and 4 courses of 5 daily doses of etoposide over 24 weeks.<sup>92</sup> Dactinomycin and doxorubicin are given together, and cyclophosphamide and etoposide are given together. Regimen M starts at week 7 for tumors requiring augmentation of therapy based on molecular markers or response of lung metastases to 6

weeks of DD4A. Regimen I consists of 9 doses of vincristine, 4 doses of doxorubicin (cumulative dose 180 mg/m<sup>2</sup>), 7 courses of 3 to 5 daily doses of cyclophosphamide, and 3 courses of 5 daily doses of etoposide.<sup>11,61,94</sup> Doxorubicin and 3 daily doses of cyclophosphamide are given together, and 5 daily doses of cyclophosphamide and etoposide are given together. Depending on when surgery is done, regimen I starts at week 7, 9, or 12 for tumors requiring augmentation of therapy based on histology.

### Neoadjuvant Chemotherapy

Neoadjuvant chemotherapy regimens are used for patients with a contraindication to or inability to undergo upfront nephrectomy and include (1) EE4A, (2) DD4A, or (3) VAD (see “Principles of Chemotherapy” [WILMS-G] in the algorithm). The specific neoadjuvant regimens depend on the setting and are described in the algorithm (see “Principles of Chemotherapy” [WILMS-G] in the algorithm). At week 6 of neoadjuvant chemotherapy, the tumor(s) are reimaged to determine if they are now resectable. If present, pulmonary lesions can be used to assess response to neoadjuvant chemotherapy. Persistent pulmonary lesions may be considered for removal after 6 weeks of chemotherapy, if they can be removed without

## PRINCIPLES OF ABDOMINAL MASS EVALUATION

**Initial Evaluation (complete history and physical exam, including laboratory and blood pressure assessment)**

- Evaluate prior medical and family history.
- Identify any congenital anomalies.
- Note location and size of abdominal mass. Palpate abdomen gently to avoid tumor rupture.
- Mass may be smooth and non-tender; assess for bilateral lesions.
- Varicocele secondary to obstruction of the spermatic vein, ascites, and lower extremity edema may be associated with presence of tumor in inferior vena cava (IVC).
- CBC with differential, comprehensive metabolic panel, coagulation panel, UA noting the presence or absence of protein and white or red blood cells, and urine VMA/HVA to evaluate for neuroblastoma
- A healthy-appearing child with abdominal distention is more likely to have WT, whereas an ill-appearing child may have neuroblastoma.
- Extension of a tumor thrombus into the right atrium may increase the risk for pulmonary emboli.

**Differential Diagnosis****Benign Conditions**

- Adrenal hemorrhage
- Angiomyolipoma
- Cystic nephroma
- Dysplastic kidney
- Hydronephrosis
- Metanephric tumors (adenoma, stromal tumor, adenofibroma)
- Multicystic kidney disease
- Nephroblastomatosis
- Polycystic kidney disease
- Renal hemorrhage
- Renal vein thrombosis

**Malignant Conditions**

- Clear cell sarcoma of the kidney (CCSK)
- Ewing sarcoma
- Hepatoblastoma
- Burkitt lymphoma
- Congenital mesoblastic nephroma
- Nephroblastoma (WT)
- Neuroblastoma
- Renal cell carcinoma (including renal medullary carcinoma)
- Rhabdomyosarcoma
- Rhabdoid tumor of the kidney
- Rare renal tumors, including renal sarcoma, primitive neuroectodermal tumors (PNETs), *DICER1*-associated sarcoma, desmoplastic small round cell tumors (DSRCTs), renal neuroblastoma, and perivascular epithelioid cell tumors (PEComas)

Version 2.2021, 06/17/21 © National Comprehensive Cancer Network, Inc. 2021. All rights reserved.  
The NCCN Guidelines® and this illustration may not be reproduced in any form without the express written permission of NCCN.

WILMS-A

significant morbidity. In certain settings, if patients have a complete response at week 6 of chemotherapy then surgery is not needed. If there is less than a partial response after chemotherapy, an open biopsy should be considered to assess for anaplasia or to confirm diagnosis of WT. Chemotherapy is continued for a total of 12 weeks if the patient has a partial response at week 6 but is not a candidate for surgery at week 6, including NSS. However, surgery is recommended by week 12 of neoadjuvant chemotherapy based on clinical trial data showing that continuing chemotherapy beyond 12 weeks does not yield continued tumor shrinkage.<sup>70,95</sup>

**Adjuvant Chemotherapy**

Adjuvant chemotherapy regimens include (1) EE4A, (2) DD4A, (3) regimen M, and (4) regimen I (see “Principles of Chemotherapy” [WILMS-G] in the algorithm). The precise regimens that are used depend on the setting and risk stratification; for example, adjuvant chemotherapy with EE4A is recommended for children with unilateral FHWT at standard risk after upfront nephrectomy. Adjuvant chemotherapy should be initiated no later than 14 days after nephrectomy. As previously mentioned, risk stratification is used to determine the most appropriate adjuvant

chemotherapy regimens for patients (see “Initial and Final Risk Assessment for Favorable Histology Wilms Tumor” [WILMS-F] in the algorithm). If RT is also required, then timing of adjuvant chemotherapy should be coordinated to avoid administering full doses of dactinomycin or doxorubicin with radiation.

**Radiation Therapy**

The NCCN Panel recommends consulting a radiation oncologist when WT is suspected to allow adequate time for radiation planning if needed, including coordination with chemotherapy administration. Adjuvant RT is recommended for patients at higher risk after surgery but not for those with low stage, lower risk disease. Depending on the setting, adjuvant flank RT or WAI with or without whole lung irradiation may be recommended. For example, adjuvant flank RT is recommended for patients who have local stage III FHWT or stage IV with local stage III.<sup>96</sup> Local stage III refers to staging at the primary site regardless of metastases [see “Children’s Oncology Group (COG) Staging of Wilms Tumor,” available in these guidelines at NCCN.org]. Biopsy alone does not upstage a tumor to stage III for determining whether to give adjuvant RT. Testicular shielding is recommended for most boys receiving

## PRINCIPLES OF IMAGING

**General Principles**

Imaging is essential for diagnosis, staging, and surveillance of renal tumors. Ultimately tumor staging remains surgical, but as therapies continue to evolve, preoperative imaging evaluation is becoming more important for staging.<sup>1</sup>

**Goals of Imaging**

- Differentiate primary renal tumors from primary extra-renal tumors.
- Evaluate the involved and contralateral kidney.
- Assess for the presence of two kidneys and determine the location of the involved kidney (renal fossa vs. ectopic).
- Define extent of tumor in preparation for resection and radiation therapy (RT).
- Assess patency of the renal vein and IVC. Assess for tumor thrombus extending through the renal vein and IVC (can occur in 10% of cases), and determine extent of thrombus in the IVC and/or renal vein, if present.
- Evaluate abdomen and lungs for presence of metastatic spread.
- Provide surveillance in high-risk populations and following therapy.

**Imaging: Ultrasound (US)**

- First-line modality for the assessment of abdominal masses in the pediatric population given the lack of radiation and the ability to perform the US without sedation.
- Allows determination of origin of abdominal mass from the kidney given that renal masses typically distort the renal parenchyma with a “claw sign” surrounding the mass.
- Identifies contralateral kidney, liver evaluation, and presence or absence of tumor extension into the renal vein or IVC.

**Imaging: CT/MRI**

- Abdominal CT or MRI is recommended after US to better evaluate the overall extent and involvement of the renal mass.<sup>2</sup> However, both modalities may require some level of sedation, especially MRI, and should be performed after an initial assessment with US.
- Pelvic CT or MRI may also be performed if the mass is assumed to extend to the pelvis.
- Abdominal CT and MRI have been shown to be equivalent in the initial assessment of WT.<sup>3</sup>
- If abdominal CT is performed, portal venous phase timing is recommended and multiphase imaging is not required.<sup>4</sup>
- Prior to CT and MRI scan, renal function should be assessed by determining an estimated glomerular filtration rate (GFR).
- CT or MRI imaging of the abdomen and pelvis should assess for:
  - ▶ Volume of tumor
  - ▶ Evidence of tumor rupture
  - ▶ Evidence of tumor thrombus extension into the renal vein or IVC
  - ▶ Symmetric excretion of contrast
- CT of the chest is also recommended to assess for pulmonary metastases. If concerned with mediastinal/thoracic hilar involvement, contrast may be helpful. While CT and MRI are equivalent for the abdomen, chest CT is superior to chest MRI for evaluation of lung metastases.

**Post-Treatment Surveillance<sup>5,6</sup>**

- Chest and abdominal imaging every 3 months for 2 years, then every 6 months for 2 years
- Chest x-ray and abdominal US may be used in place of cross-sectional imaging with chest CT and abdominal CT or MRI

1 Chung EM, Graeber AR, Conran RM. Renal Tumors of Childhood: Radiologic-Pathologic Correlation Part 1. The 1st Decade: From the Radiologic Pathology Archives. *Radiographics* 2016;36:499-522.

2 McDonald K, Duffy P, Chowdhury T, McHugh K. Added value of abdominal cross sectional imaging (CT or MRI) in staging Wilms' Tumor. *Clin Radiol* 2013;68:16-20.

3 Sarvaes S, Khanna G, Naranjo A, et al. Comparison of diagnostic performance of CT and MRI for abdominal staging of pediatric renal tumors: a report from the Children's Oncology Group. *Pediatr Radiol* 2015;45:166-72.

4 Brisse HJ, Smets AM, Kaste SC, Owens CM. Imaging in unilateral Wilms Tumour. *Pediatr Radiol* 2008;38:18-29.

5 Brok J, Lopez-Yurda M, Tinteren HV, et al. Relapse of Wilms' tumour and detection methods: a retrospective analysis of the 2001 Renal Tumour Study Group-International Society of Paediatric Oncology Wilms' tumour protocol database. *Lancet Oncol* 2018;19:1072-1081.

6 Mullen EA, Chi YY, Hibbitts E, et al. Impact of surveillance imaging modality on survival after recurrence in patients with favorable-histology Wilms Tumor: a report from the Children's Oncology Group. *J Clin Oncol* 2018;36:3396-3403.

Version 2.2021, 06/17/21 © National Comprehensive Cancer Network, Inc. 2021. All rights reserved.  
The NCCN Guidelines® and this illustration may not be reproduced in any form without the express written permission of NCCN.

WILMS-B

adjuvant flank RT. WAI is recommended for patients with cytology-positive ascites, any preoperative tumor rupture, peritoneal seeding, and diffuse surgical spillage.<sup>81,97</sup> Supplemental boost irradiation is recommended for gross residual disease that remains after adjuvant flank RT or WAI. For each setting, the algorithm provides detailed recommendations for adjuvant flank RT, WAI, and whole lung irradiation; the RT target volumes, techniques, and schedules are also provided in the supplementary pages (see “Principles of Radiation Therapy for FHWT” [WILMS-H] in the algorithm).

Adjuvant whole lung irradiation is recommended for patients with lung metastases; intensity-modulated RT (IMRT) or anteroposterior/posteroanterior (AP/PA) may be used.<sup>98–100</sup> However, adjuvant whole lung irradiation can be delayed until week 6 of chemotherapy in select patients with FHWT who only have metastases in the lung. If patients with FHWT but no 1q gain and no LOH at 1p and 16q have a complete response of their lung metastases to 6 weeks of chemotherapy, then whole lung irradiation is not recommended; however, whole lung irradiation is recommended for patients with 1q gain or LOH at 1p and 16q. Studies show that starting RT later than 14 days after surgery is associated with an increased risk of

abdominal recurrence in patients without metastases.<sup>101</sup> The NCCN Panel recommends that RT should start ideally by day 10 after surgery but no later than day 14.<sup>102,103</sup> However, patient factors should be considered when deciding about the timing of adjuvant RT, including age and need to assess the response of lung metastases to chemotherapy when giving WAI and whole lung irradiation. If RT is being considered, the timing of RT should be coordinated with chemotherapy to avoid the coadministration of full doses of dactinomycin or doxorubicin with RT (see “Principles of Chemotherapy” [WILMS-G] in the algorithm). Dactinomycin or doxorubicin can be administered at full doses before starting RT.

**Treatment: Individual Settings**

The NCCN recommendations for treatment of children with FHWT are based on clinical trial data from the COG, and older NWTS trials, that have been used to identify treatment regimens that can increase survival and decrease relapse, morbidity, and long-term adverse events.<sup>104</sup> The clinical trials performed in Europe by the International Society of Pediatric Oncology (SIOP) have typically used neoadjuvant therapy followed by surgery even if the tumor was initially resectable. The only setting

## PRINCIPLES OF PATHOLOGY

**Gross Examination**

- Most tumors are unifocal
- Multifocal tumors in a single kidney (7%)
- Bilateral primary tumors (5%–10%)
- Solitary, rounded, multinodular masses sharply demarcated from adjacent kidney by a fibrous capsule
- Cut surface – pale gray/tan, soft, or firm (stromal components)
- Preoperative chemotherapy induces necrosis

**Histopathology of Favorable Histology Wilms Tumor (FHWT)**

- FHWT implies the absence of focal or diffuse anaplasia.
- Undifferentiated blastemal cells
  - ▶ Blastemal cells are small, closely packed cells that have round to oval nuclei with scant cytoplasm. They have evenly distributed coarse chromatin, small nucleoli, and are mitotically active. Blastemal predominant tumors (66% of tumor) are aggressive, invasive, and present with advanced stage, but are responsive to chemotherapy.
- Cells that are differentiated towards epithelial and stromal lineages
  - ▶ Epithelial cells are arranged in early tubular forms resembling primitive, rosette-like structures, which mimic tubular and glomerular elements. Epithelial lineage-predominant tumors are associated with a low risk of failure after treatment, but frequently have a poor response to chemotherapy.
  - ▶ Stromal patterns include:
    - ◊ Smooth muscle and fibroblastic differentiation
    - ◊ Spindle cells in a myxoid background
    - ◊ Skeletal muscle, adipose tissue, cartilage, bone, ganglion cells, and neuroglial tissue with heterologous stromal differentiation.
- Completely necrotic cells
- The most characteristic pattern is the triphasic pattern, in which blastema, epithelial, and stromal lineages are all present. However, biphasic and monophasic patterns also exist, and heterologous non-renal elements also occur. The tumor corresponds to stages of normal/abnormal nephrogenesis.
- An additional important microscopic characteristic of WT is the presence of a peritumoral fibrous capsule that demarcates the tumor from adjacent renal parenchyma.
- Chemotherapy-induced changes include necrosis, foamy macrophages, hemosiderin deposits, and fibrosis. Chemotherapy induces maturation of blastemal, epithelial, and stromal components with striated muscle differentiation being the most common. At times there is an excellent response to chemotherapy and the tumor is totally necrotic.

**Pattern of Spread**

- WTs extend locally into the perirenal soft tissues, renal vein, and vena cava.
- WTs metastasize to the lungs, regional LNs, and the liver.
- WTs rarely metastasize to bone and brain tissues, which differentiates WT from other kidney cancers, clear cell sarcomas, or rhabdoid tumors.

**Molecular Markers**

- Unfavorable biomarkers include 1q gain and/or loss of heterozygosity (LOH) in 1p and 16q. There are less data for using 11p15 LOH or LOI as unfavorable biomarkers. There are no data for using chromosome 17p13 to direct therapy.
- FHWTs almost never exhibit *TP53* gene mutations.
  - ▶ *TP53* positivity in absence of anaplasia may represent progression events closely linked to development of anaplasia.

Version 2.2021, 06/17/21 © National Comprehensive Cancer Network, Inc. 2021. All rights reserved.  
The NCCN Guidelines® and this illustration may not be reproduced in any form without the express written permission of NCCN.

WILMS-C

where NCCN recommendations are based on SIOP guidelines is the management of unilateral, initially unresectable tumors (see “Localized Unilateral Renal Tumor With a Predisposing Condition,” page 966). By treating for presumed diagnosis, SIOP accepts that a percentage of patients will be misdiagnosed as having WT (ie, false positive). NWTS/COG believe it is important to establish histology at the start because not all renal tumors are WT. COG treatments are also based on inclusion stage, and on genetic risk factors in the tumor at diagnosis, requiring tumor tissue. Most children with WT have unilateral disease and upfront nephrectomy with regional lymph node sampling is recommended followed by adjuvant therapy, which is selected based on an assessment of the risk after surgery (see “Initial and Final Risk Assessment for Favorable Histology Wilms Tumor” [WILMS-F] in the algorithm).

Molecular testing of tumor tissue (eg, LOH and 1q gain) is recommended to use in risk assessment for all newly diagnosed patients with FHWT.<sup>105</sup> The goal is to select therapy that will increase survival and decrease relapse, morbidity, and long-term adverse events. Patients are categorized as (1) very low risk, (2) low risk, (3) standard risk, (4) higher risk, and (5) bilateral (see “Initial and Final

Risk Assessment for Favorable Histology Wilms Tumor” [WILMS-F] in the algorithm). Final risk assessment includes tumor biology and response of pulmonary nodules to initial therapy; final risk assessment is used when deciding whether to continue the initial chemotherapy or switch to more intensive (augmented) chemotherapy. The goal of therapy is to avoid relapse. Risk of toxicity with intensification needs to be balanced with risk of relapse, and consequent need for very intensive therapy, with much less chance of cure after relapse. If patients with FHWT relapse after initial treatment, the salvage rate depends on the number of drugs administered with initial chemotherapy and whether RT was given with the initial treatment.<sup>106,107</sup> In addition, regimens to treat relapse are associated with late effects, such as cardiomyopathy, second malignancy, infertility, and renal insufficiency. The NCCN Panel recommends referral for infertility risk/fertility preservation counseling for all patients treated with chemotherapy; counseling is strongly encouraged before treatment with regimen M or WAI.<sup>108,109</sup> Posttreatment imaging surveillance should evaluate the chest and abdomen and may consist of CT, MRI, ultrasound, or chest X-ray, which is most often done every 3 months for 2 years and then every 6 months for an additional 2 years.<sup>110,111</sup>

## PRINCIPLES OF SURGERY

**General Principles**

- Surgical exploration cannot be replaced by imaging, although CT<sup>1</sup> or MRI of the abdomen is recommended prior to surgery.
  - Determine size and extent of tumor.
  - Contralateral kidney exploration is no longer routinely performed for unilateral WT unless concerning, but indeterminate, lesion(s) seen on CT/MRI scan.
  - Assess retroperitoneal adenopathy, tumor rupture, and ascites.
  - Assess tumor involvement of renal veins or IVC.
- Evaluation of resectability prior to surgery
  - Extension of tumor thrombus above hepatic veins
  - Tumor extension to contiguous structures
  - Evaluate whether the patient is at risk for pulmonary compromise secondary to pulmonary metastases.
  - Assess risk of morbidity or mortality, gross tumor spill, or residual tumor.
  - Patients at risk for long-term renal failure may benefit from a nephron-sparing approach.<sup>2,3-5</sup>
- Transabdominal or a thoracoabdominal exposure with transperitoneal approach (preferred surgical approaches) and abdominal exploration, unilateral radical ureteronephrectomy with LN sampling.<sup>3</sup> LN sampling **MUST** be performed for adequate staging; recommend obtaining minimum >5 (nodes) from areas in renal hilum anatomically expected to represent nodes associated with kidney.<sup>4</sup>
- Primary resection provides necessary biologic information for risk stratification and selection of appropriate therapy.
  - Minimize treatment for low-risk patients.
  - Improve survival in higher risk patients.

**Contraindications to Primary Resection**

- High risk of renal failure for those with germline *WT1* mutations (Denys-Drash, WAGR) or bilateral WT. Overall risk of long-term renal failure is <1%.<sup>2</sup>
- Unacceptable anesthesia risk due to disease burden
  - Massive pulmonary disease
  - Very large abdominal tumors causing pulmonary compromise
- Surgeon judgment: Operation would lead to significant morbidity/mortality, tumor spill, or residual tumor
- Solitary kidney
- IVC tumor thrombus above the level of the hepatic veins

**Goals of Surgery for Unilateral WT**

- Complete clearance of all disease
- Accurate LN staging
- Complete pathologic evaluation
- Resection without rupture of the tumor

Continued  
ReferencesWILMS-D  
1 OF 3

Version 2.2021, 06/17/21 © National Comprehensive Cancer Network, Inc. 2021. All rights reserved.  
The NCCN Guidelines® and this illustration may not be reproduced in any form without the express written permission of NCCN.

Clinical trial data used to support the NCCN recommendations in different settings of FHWT are described in the following sections. Patients with very-low-risk, low-risk, and standard-risk FHWT were studied in the NWTS-5 and AREN0532 trials.<sup>112,113</sup> Patients with higher risk FHWT were studied in AREN0533.<sup>92</sup> Clinical trial data from NWTS-5, AREN0532, and AREN0533 are used to support the NCCN recommendations for children with unilateral renal tumors who do not have predisposing conditions.<sup>105</sup> Children with localized or metastatic unilateral renal tumor and a predisposing condition were studied in AREN0534.<sup>114</sup> Patients with bilateral FHWT were also assessed in the AREN0534 trial.<sup>61</sup>

**Unilateral Renal Tumors****Resectable Unilateral Renal Tumor With Very Low Risk****Clinical Trial Data**

Children with resectable unilateral WT typically receive upfront nephrectomy followed by adjuvant therapy.<sup>115</sup> However, data suggested that adjuvant therapy could be omitted in children who were deemed at very low risk after upfront nephrectomy.<sup>116</sup> The National Wilms Tumor Study 5 (NWTS-5) trial assessed upfront nephrectomy followed

by observation only in 77 children at very low risk after surgery.<sup>113</sup> These children were deemed at very low risk because they were younger than 2 years, their tumor weight was less than 550 g, and they had stage I disease. These 77 children who only had surgery were compared with 111 children who had surgery plus adjuvant chemotherapy with EE4A. The estimated 5-year event-free survival for observation was 84% (95% CI, 73%–91%); it was 97% (95% CI, 92%–99%;  $P=.002$ ) for EE4A. The children who relapsed after surgery alone were successfully treated with more intensive therapy than EE4A (doxorubicin and RT). The estimated 5-year overall survival for surgery only was 98% (95% CI, 87%–99%); it was 99% (95% CI, 94%–99%) for EE4A ( $P=.70$ ). At 8 years, the overall survival was still excellent (98.7%).

Data suggested that certain molecular markers in the tumors could be used to identify children who might be at higher risk after surgery alone; adjuvant chemotherapy could be used to decrease the risk of relapse in this subset.<sup>90</sup> The AREN0532 study assessed observation alone after upfront nephrectomy in children at very low risk after surgery.<sup>112</sup> The trial assessed whether observation only after surgery alone was associated with an acceptable level of survival and whether certain tumor molecular markers



## PRINCIPLES OF SURGERY (CONTINUED)

**Surgical Management: Abdominal Cavity**

- Open peritoneal cavity and reflect colon
- Explore/biopsy liver, peritoneal surfaces, and vessels for tumor extension
- Mobilize primary tumor and ligate ureter as low as possible
- Expose/dissect/ligate renal vessels
- LN sampling from renal hilum, pericaaval/para-aortic regions.<sup>4</sup> Regional LNs should be sampled from the renal hilum and paracaval and para-aortic regions. Involved or suspicious LNs should be removed, but a formal LN dissection is not necessary.
- Radical nephrectomy is completed en bloc; however, the adrenal gland does not require removal if uninvolved with the tumor<sup>6</sup>
- Careful handling of the tumor to avoid tumor spillage<sup>7-13</sup>

**Surgical Management: Pulmonary Nodules**

- Consideration at diagnosis for confirmation of metastatic disease
  - ▶ Nodules may be involved with disease in 46%–85% of patients
- If surgically resectable without significant morbidity, resect persistent pulmonary lesions following 6 weeks of chemotherapy
  - ▶ Inaccurate initial assignment of lung nodules may result in incorrect assessment of treatment response
- Salvage therapy following chemotherapy and radiotherapy
  - ▶ In order to avoid intensive salvage regimens, any new pulmonary lesions should be confirmed histologically

**Summary of Surgical Approach to Bilateral WT**

- Do not biopsy upon presentation of bilateral WT.
- Use of standardized 3-drug neoadjuvant chemotherapy (VAD, See WILMS-G) followed by bilateral nephron-sparing surgery (NSS) to preserve renal function
  - ▶ Possible criteria for successful NSS:
    - ◇ Small tumor size
    - ◇ Peripheral or polar location of the mass
    - ◇ Lack of invasion or encasement of renal vessels
  - ▶ Relative contraindications to NSS:
    - ◇ Central location
    - ◇ Proximity to the renal vessels
- Week 6 re-evaluation:
  - ▶ Perform surgery if bilateral NSS is possible
  - ▶ For less than a partial response to chemotherapy, consider open biopsy to assess for presence of anaplasia
  - ▶ Continue chemotherapy if patient has some response but is not a candidate for NSS
- Surgery should be performed within 12 weeks of starting neoadjuvant therapy
  - ▶ Aim for bilateral NSS, if possible
  - ▶ If operating after chemotherapy, enucleation is safe
- If disease recurrence, repeat NSS

## References

Version 2.2021, 06/17/21 © National Comprehensive Cancer Network, Inc. 2021. All rights reserved. The NCCN Guidelines® and this illustration may not be reproduced in any form without the express written permission of NCCN.

WILMS-D  
2 OF 3

were associated with increased risk of relapse. The goal was to avoid adjuvant chemotherapy with EE4A, if feasible, and thus decrease toxicity. For the 116 children observed after surgery alone, the overall survival was 100%; the estimated 4-year event-free survival was 89.7% (95% CI, 84.1%–95.2%). Tumors with 11p15 LOH or LOI were associated with a 20%–25% risk of recurrence, whereas the relapse risk was only 3% in tumors without 11p15 LOH or LOI. One patient who relapsed had combined LOH of 1p and 16q in addition to 11p15 LOH. The greatest difference between the NWTS very-low-risk cohort and the COG very-low-risk cohort was prospective central review for stage and histology, and requirement of lymph node sampling. Patients were not excluded for finding of unfavorable biology and outcomes were still excellent. Retrospective analysis showed impact of LOH/LOI of 11p15.

**NCCN Recommendations**

Children with FHWT fitting the criteria of the COG very-low-risk group can be observed without adjuvant therapy or receive adjuvant chemotherapy with EE4A (see “Unilateral FHWT, Primary Nephrectomy” [WILMS-3] in the algorithm).<sup>112,113</sup> EE4A is recommended for children

with very-low-risk clinical features but with unfavorable prognostic molecular markers (1p15 LOH or LOI or combined LOH at 1p and 16q). Observation only after surgery is recommended for children without these unfavorable biomarkers. Postoperative RT is not recommended for stage I disease.

**Low Risk****Clinical Trial Data**

The NWTS-5 trial showed that certain unfavorable tumor molecular markers were associated with poorer relapse-free survival in children with stage I and II FHWT.<sup>90</sup> When treated with adjuvant EE4A, children with stage I or II FHWT with combined LOH at 1p and 16q had a 4-year relapse-free survival of 74.9% versus 91.2% for those without these markers ( $P=.001$ ). The AREN0532 and AREN0533 trials showed that intensifying (ie, augmenting) adjuvant therapy to DD4A improved relapse-free survival for patients with stage I or II FHWT with combined LOH at 1p and 16q compared with historical controls from NWTS-5.<sup>105</sup>

For patients with stage I or II FHWT plus combined LOH 1p and 16q, the estimated 4-year event-free survival was 68.8% (95% CI, 55.2%–82.3%) with EE4A on NWTS-5

## PRINCIPLES OF SURGERY REFERENCES

- <sup>1</sup> Khanna G, Rosen N, Anderson JR, et al. Evaluation of diagnostic performance of CT for detection of tumor thrombus in children with Wilms tumor: a report from the Children's Oncology Group. *Pediatr Blood Cancer* 2012 Apr;58:551-555.
- <sup>2</sup> Breslow NE, Collins AJ, Ritchey ML, et al. End stage renal disease in patients with Wilms tumor: results from the National Wilms Tumor Study Group and the United States Renal Data System. *J Urol* 2005;174:1972-1975.
- <sup>3</sup> Aldrink JH, Heaton TE, Dasgupta R, et al. Update on Wilms tumor. *J Pediatr Surg* 2019;54:390-397.
- <sup>4</sup> Qureshi SS, Bhagat M, Kazi M, et al. Standardizing lymph nodal sampling for Wilms tumor: a feasibility study with outcomes. *J Pediatr Surg* 2020;55:2668-2675.
- <sup>5</sup> Kieran K, Ehrlich PF. Current surgical standards of care in Wilms tumor. *Urol Oncol* 2016;34:13-23.
- <sup>6</sup> Kieran K, Anderson JR, Dome JS, et al. Is adrenalectomy necessary during unilateral nephrectomy for Wilms Tumor? A report from the Children's Oncology Group. *J Pediatr Surg* 2013;48:1598-1603.
- <sup>7</sup> Gow K, Barnhart DC, Hamilton TE, et al. Primary nephrectomy and intraoperative tumor spill: report from the Children's Oncology Group (COG) Renal Tumors Committee. *J Pediatr Surg* 2013;48:34-38.
- <sup>8</sup> D'Angio GJ, Breslow N, Beckwith JB, et al. The treatment of Wilms' tumor: results of the National Wilms' Tumor Study. *Cancer* 1976;38:633-646.
- <sup>9</sup> D'Angio GJ. Editorial: SIOP (International Society of Paediatric Oncology) and the management of Wilms' tumor. *J Clin Oncol* 1983;1:595-596.
- <sup>10</sup> Kalapurakal JA, Li SM, Breslow NE, et al. Intraoperative spillage of favorable histology Wilms tumor cells: influence of irradiation and chemotherapy on abdominal recurrence. A report from the National Wilms Tumor Study Group. *Int J Rad Oncol Biol Phys* 2010;76:201-206.
- <sup>11</sup> Jereb B, Burgers JM, Tournade MF, et al. Radiotherapy in the SIOP (International Society of Pediatric Oncology) nephroblastoma studies: a review. *Med Pediatr Oncol* 1994; 22:221-227.
- <sup>12</sup> Lemerle J, Vourte PA, Tournade MF, et al. Effectiveness of preoperative chemotherapy in Wilms' tumor: results of an International Society of Pediatric Oncology (SIOP) clinical trial. *J Clin Oncol* 1983;1:604-609.
- <sup>13</sup> Tournade MF, Com-Nougues C, de Kraker J, et al. Optimal duration of preoperative therapy in unilateral and nonmetastatic Wilms' tumor in children older than 6 months: results of the Ninth International Society of Pediatric Oncology Wilms' Tumor Trial and Study. *J Clin Oncol* 2001;19:488-500.

Version 2.2021, 06/17/21 © National Comprehensive Cancer Network, Inc. 2021. All rights reserved.  
The NCCN Guidelines® and this illustration may not be reproduced in any form without the express written permission of NCCN.

WILMS-D  
3 OF 3

and 87.3% (95% CI, 75.1%–99.5%) with DD4A on AREN0532 ( $P=.042$ ).<sup>105</sup> All 4 relapses occurred in patients with stage II FHWT who received DD4A. For patients with stage I or II FHWT and LOH at 1p and 16q, the estimated 4-year overall survival was 91.6% (95% CI, 83.6%–99.6%) with EE4A on NWTS-5 and 100% with DD4A on AREN0532 ( $P=.096$ ).<sup>105</sup> It is important to note that the AREN0532 and AREN0533 trials were not sufficiently powered to detect statistical differences in overall survival with augmented therapy (DD4A), because combined LOH 1p and 16q occurs at low frequencies (4.27% [49/1147]) in patients with stage I or II FHWT. The impact of intensification for finding of 1q gain has not been studied.

### NCCN Recommendations

Children with FHWT at low risk after surgery can receive adjuvant therapy with regimen EE4A or switch to regimen DD4A (see “Unilateral FHWT, Primary Nephrectomy” [WILMS-3] in the algorithm).<sup>105</sup> DD4A is recommended for children with low-risk tumors that express combined LOH 1p and 16q. EE4A can be continued for children with tumors that do not have these unfavorable biomarkers. Postoperative RT is not recommended for local stage I and II disease.

### Standard Risk and Higher Risk

#### Clinical Trial Data

The NWTS-5 trial showed that certain unfavorable tumor molecular markers were associated with poorer relapse-free survival in children with stage III or IV FHWT.<sup>90</sup> When treated with adjuvant DD4A, children with stage III or IV FHWT with combined LOH at 1p and 16q had a 4-year relapse-free survival of 65.9% versus 83% for those without these unfavorable biomarkers ( $P=.01$ ). AREN0533 showed that augmenting adjuvant therapy to regimen M at week 7 improved relapse-free survival for 51 patients with stage III or IV FHWT plus combined LOH 1p and 16q compared with historical controls from NWTS-5.<sup>92,105,112</sup> For patients with stage III WT plus combined LOH 1p and 16q treated with regimen M, the estimated 4-year event-free survival was 87.1% (95% CI, 75.1%–99.1%) and the estimated 4-year overall survival was 93.6% (95% CI, 84.6%–100%). For patients with stage IV WT plus combined LOH 1p and 16q treated with regimen M, the estimated 4-year event-free survival was 95.0% (95% CI, 84.9%–100%) and the estimated 4-year overall survival was 100%. Four relapses and two second malignancies occurred in patients with stage III or IV FHWT treated with regimen M.

## PRINCIPLES OF BIOPSY

- Routine pre-nephrectomy biopsy for resectable renal tumors is contraindicated due to the risk of recurrence from tumor spill. Further, tumor biopsy will automatically upstage the local stage to III, which in turn mandates additional cardiotoxic chemotherapy (doxorubicin) and RT (for treatment of those with unilateral tumor without a predisposing condition).
- The only situation in which a biopsy is recommended is when the tumor is deemed unresectable in patients with a unilateral tumor without a predisposing condition. If a biopsy is thus considered, there are two possible options: 1) an open posterior approach—done to avoid intra-abdominal spill; or 2) percutaneous core needle biopsies (fine-needle aspirates are not recommended). In both instances, sufficient tissue must be obtained so that all necessary tests may be performed. Identification of anaplasia may be difficult by either biopsy technique.
- If surgical exploration is performed with intent to resect but the tumor is deemed unresectable, then open biopsy should be performed.

Version 2.2021, 06/17/21 © National Comprehensive Cancer Network, Inc. 2021. All rights reserved.  
The NCCN Guidelines® and this illustration may not be reproduced in any form without the express written permission of NCCN.

WILMS-E

For patients with stage III or IV FHWT plus combined LOH 1p and 16q treated with DD4A, the estimated 4-year event-free survival was 61.3% (95% CI, 44.9%–77.6%) for NWTS-5 and 90.2% (95% CI, 81.7%–98.6%) with regimen M on AREN0532 and AREN0533 ( $P=.001$ ).<sup>105</sup> For patients with stage III or IV FHWT plus combined LOH 1p and 16q, the estimated 4-year overall survival was 86.0% (95% CI, 74.5%–97.5%) with DD4A on NWTS-5 and 96.1% (95% CI, 90.5%–100%) with regimen M on AREN0532 and AREN0533 ( $P=.087$ ).<sup>105</sup> Some clinicians have concerns regarding the comparability of historical control data that were used to justify augmenting therapy with regimen M due to the historical control group that was used.<sup>117,118</sup>

Because combined LOH 1p and 16q occurs at low frequencies (6.01% [82/1364]) in patients with stage III or IV FHWT, the AREN0532 and AREN0533 trials were not powered to detect statistical differences in overall survival with augmented therapy. A different molecular marker, 1q gain, occurs more frequently and is associated with inferior survival; 1q gain has been assessed in several studies, including patients with stage IV FHWT.<sup>8,89,92,119</sup> The marker, 1 q gain, identifies higher risk patients with isolated lung metastases (ie, lung-only metastases) who

should receive whole lung irradiation even if their lung metastases have completely responded to initial DD4A.<sup>92</sup> However, lung RT can be omitted in patients with lung-only metastases and no unfavorable markers (ie, no 1q gain, no combined LOH 1p and 16q) who have a complete response of their lung metastases to initial DD4A. Although 1q gain has been identified as an adverse prognostic factor, no prospective studies have been done to show that intensification of therapy is more effective. The impact of 1q gain is greatest in higher risk; it is up to the clinician and family to consider risks and benefits of intensification with known treatment regimens. 1q gain can be used to identify patients who are not appropriate for deintensification of therapy, such as patients with rapid complete response of lung nodules. Those with rapid complete response and 1 q gain have a high risk of relapse if they are not treated with RT and DD4A (ie, event-free survival of 57%).

Regimen M may cause morbidity (eg, enhanced myelosuppression) and late effects including secondary leukemia (caused by cyclophosphamide and etoposide) and infertility (caused by cyclophosphamide).<sup>92,120,121</sup> However, regimens to treat relapse are also associated with late effects, such as cardiomyopathy, second malignancy,

INITIAL AND FINAL RISK ASSESSMENT FOR FAVORABLE HISTOLOGY WILMS TUMOR

- Risk-based therapy is determined by tumor stage, histologic classification, molecular markers, and, when indicated, initial response to chemotherapy. Risk stratification is used to assign most appropriate therapy to patients, with a goal of maximizing good outcome while balancing risk of toxicity of therapies. Risk stratification has evolved through multiple large collaborative clinical trials. Current risk stratification includes consideration of tumor histology, histopathologic and surgical stage, tumor biology (LOH of 1p and 16q), presence of metastatic or bilateral disease, and clinical factors such as patient age, known predisposition syndromes, and response of pulmonary lesions to initial therapy. Additional tumor biomarkers have been associated with increased risk of relapse (LOH and LOI of 1p and 16q, 1q gain), but alteration of therapy has not yet been studied.
- Cytogenetic and molecular testing are recommended for all newly diagnosed FHWT to assess for unfavorable biomarkers, including chromosome 1q gain and/or LOH in chromosomes 1p and 16q.<sup>1,2</sup> There are less data for using 11p15 LOH or LOI as unfavorable biomarkers. There are no data for using chromosome 17p13 to direct therapy. Results from molecular testing can be obtained in 2 weeks.
- Initial risk is based on age, clinical, radiographic, surgical, and pathologic findings.
- Final risk is based on initial risk plus LOH at 1p and 16q, and response of lung metastases at week 6.

Patient Age	Tumor Weight	Stage	Initial Risk Group	LOH 1p/16q	Lung Metastases Response	Extra-Pulmonary Metastases	Final Risk Group
<2 years	<550 g	I	Very Low	Any	N/A	N/A	Very Low
Any	≥550 g	I	Low	No	N/A	N/A	Low
≥2 years	Any	I	Low	No	N/A	N/A	Low
Any	Any	II	Low	No	N/A	N/A	Low
Any	≥550 g	I	Low	Yes	N/A	N/A	Standard
≥2 years	Any	I	Low	Yes	N/A	N/A	Standard
Any	Any	II	Low	Yes	N/A	N/A	Standard
Any	Any	III	Standard	No	N/A	N/A	Standard
Any	Any	IV	Higher	No	Complete	No	Standard
Any	Any	III	Standard	Yes	N/A	N/A	Higher
Any	Any	IV	Higher	Yes	Any	Any	Higher
Any	Any	IV	Higher	Any	Partial	Any	Higher
Any	Any	IV	Higher	Any	Any	Yes	Higher
Any	Any	V	Bilateral	Any	Any	Any	Bilateral

**Prognostic Factors**

- Stage (See ST-1\*)
- Histology (favorable or unfavorable/anaplastic)
- Patient age at diagnosis
- Tumor weight
- Completeness of lung nodule response to therapy at week 6
- LOH of chromosomes 1p, 11p15, and 16q
  - LOI of 11p15
- Chromosome 1q gain<sup>1</sup>

<sup>1</sup> Gratias EJ, Dome JS, Jennings LJ, et al. Association of chromosome 1q gain with inferior survival in favorable-histology wilms tumor: a report from the Children's Oncology Group. *J Clin Oncol* 2016;34:3189-3194.  
<sup>2</sup> Grundy PE, Breslow NE, Li S, et al. Loss of heterozygosity for chromosomes 1p and 16q is an adverse prognostic factor in favorable-histology Wilms tumor: a report from the National Wilms Tumor Study Group. *J Clin Oncol* 2005;23:7312-7321.

\*Available online, in these guidelines, at NCCN.org.

Version 2.2021, 06/17/21 © National Comprehensive Cancer Network, Inc. 2021. All rights reserved. The NCCN Guidelines® and this illustration may not be reproduced in any form without the express written permission of NCCN.

WILMS-F

and renal insufficiency. In patients who have stage III FHWT and who relapse, the salvage rate is 50% or less. Thus, clinicians need to balance the possibility of late effects with regimen M versus the possibility of relapse without regimen M and also side effects associated with the salvage regimens. The NCCN Panel recommends referral for infertility risk/fertility preservation counseling for all patients treated with chemotherapy; counseling is strongly encouraged before treatment with regimen M or WAI.

**NCCN Recommendations**

DD4A is recommended for patients with stage III FHWT classified as standard risk after the initial risk assessment.<sup>105</sup> At week 6 of DD4A, the results of molecular testing from diagnostic tissue are used to determine the final risk assessment and to select further therapy. Switching to augmented therapy with regimen M is recommended for patients with combined LOH of 1p and 16q who are at increased risk. Flank RT or WAI is recommended for patients with local stage III. If RT is being considered, the timing of RT should be coordinated with chemotherapy to avoid the coadministration of full doses of dactinomycin or doxorubicin with RT.

DD4A is recommended as initial therapy for patients with stage IV FHWT classified as higher risk. At week 6 of DD4A, results of molecular testing from diagnostic tissue and of imaging are used to determine the final risk assessment and to select further therapy. Switching to augmented therapy with regimen M is recommended for patients with (1) combined LOH of 1p and 16q; or (2) lung metastases that have slow incomplete response after 6 weeks of chemotherapy. DD4A is continued after week 6 in patients with lung-only metastases that respond completely after 6 weeks of chemotherapy and in patients with extrapulmonary metastases (with or without lung metastases). However, regimen M is associated with a greater risk of toxicity, including second cancers and infertility due to cyclophosphamide and etoposide. Although patients with extrapulmonary metastases were switched to regimen M in a recent study (AREN0533), the results have not been published yet; therefore, this regimen is not currently recommended in this setting.

Postoperative flank RT or WAI is recommended for patients with local stage III disease who have higher risk disease. Whole lung irradiation may also be recommended depending on the setting. For example, whole lung irradiation is recommended for patients with tumors

## PRINCIPLES OF CHEMOTHERAPY

**General Principles**

- The administration of adjuvant, and in some cases neoadjuvant, chemotherapy in combination with surgery ± radiation markedly improves survival for FHWTs.
- Selection of the appropriate chemotherapy regimen is based on tumor histology, stage, tumor weight, the patient's age, response of lung metastases (when present) to chemotherapy, and molecular markers, which together determine the risk group (see Risk Assessment for FHWT [WILMS-F]).
- Adjuvant chemotherapy should be started within 7 to 14 days of up-front nephrectomy and the timing should be coordinated with radiation, if it is required, to avoid co-administration of full doses of dactinomycin or doxorubicin with radiation. Dactinomycin and doxorubicin can be administered at full doses prior to the start of radiation.
- Neoadjuvant chemotherapy is administered for unresectable tumors or tumors for which NSS is indicated (see Principles of Surgery [WILMS-D]) to reduce the size of the tumor(s).
  - ▶ Re-image after 6 weeks of neoadjuvant chemotherapy to determine whether the tumor(s) is/are resectable.
  - ▶ The postoperative adjuvant chemotherapy regimen is determined by tumor histology, stage, and molecular markers.

**Chemotherapy Regimens**

- **EE4A:** 13 doses of vincristine and 7 doses of dactinomycin administered over 18 weeks.<sup>1,2</sup>
- **DD4A:** 15 doses of vincristine, 5 doses of dactinomycin, and 4 doses of doxorubicin (cumulative dose 150 mg/m<sup>2</sup>) administered over 24 weeks with alternating doses of dactinomycin and doxorubicin.<sup>1,2</sup>
- **VAD:** 6–12 doses of vincristine, 2–4 doses of dactinomycin, and 2–4 doses of doxorubicin (cumulative dose 70–140 mg/m<sup>2</sup>) administered over 6–12 weeks used only in the neoadjuvant setting for patients who are candidates for NSS. In this regimen dactinomycin and doxorubicin are given together.<sup>3</sup>
- **Regimen M:** 9 doses of vincristine, 5 doses of dactinomycin, 5 doses of doxorubicin (cumulative dose 150 mg/m<sup>2</sup>), 4 courses of 5 daily doses of cyclophosphamide, and 4 courses of 5 daily doses of etoposide over 24 weeks. Dactinomycin and doxorubicin are given together, and cyclophosphamide and etoposide are given together. This regimen starts at week 7 for tumors requiring augmentation of therapy based on molecular markers or response of lung metastases to 6 weeks of DD4A.<sup>4</sup>
- **Regimen I:** 9 doses of vincristine, 4 doses of doxorubicin (cumulative dose 180 mg/m<sup>2</sup>), 7 courses of 3 to 5 daily doses of cyclophosphamide, and 3 courses of 5 daily doses of etoposide. Doxorubicin and 3 daily doses of cyclophosphamide are given together, and 5 daily doses of cyclophosphamide and etoposide are given together. This regimen starts at week 7 for tumors requiring augmentation of therapy based on histology.<sup>3,5,6</sup>

<sup>1</sup> Green DM, Breslow NE, Beckwith JB, et al. Comparison between single-dose and divided-dose administration of dactinomycin and doxorubicin for patients with Wilms' Tumor: a report from the National Wilms' Tumor Study Group. *J Clin Oncol* 1998;16:237-245.

<sup>2</sup> Green DM, Breslow NE, Beckwith JB, et al. Effect of duration of treatment on treatment outcome and cost of the treatment for Wilms' tumor: a report from the National Wilms' Tumor Study Group. *J Clin Oncol* 1998;16:3744-3751.

<sup>3</sup> Ehrlich PF, Chi YY, Chintagumpala MM, et al. Results of the first Prospective Multi-Institutional Treatment Study in Children with Bilateral Wilms Tumor (AREN0534): A report from the Children's Oncology Group. *Ann Surg* 2017;266:470-478. Correction in: *Ann Surg* 2018;267:e64.

<sup>4</sup> Dix DB, Seibel NL, Chi YY, et al. Treatment of Stage IV Favorable Histology Wilms Tumor With Lung Metastases: A Report From the Children's Oncology Group AREN0533 Study. *J Clin Oncol* 2018;36:1564-1570.

<sup>5</sup> Dome JS, Cotton CA, Perlman EJ, et al. Treatment of anaplastic histology Wilms' tumor: results from the fifth National Wilms' Tumor Study. *J Clin Oncol* 2006;24:2352-2358.

<sup>6</sup> Seibel NL, Chi YY, Perlman EJ, et al. Impact of cyclophosphamide and etoposide on outcome of clear cell sarcoma of the kidney treated on the National Wilms Tumor Study-5 (NWT5-5). *Pediatr Blood Cancer* 2019;66:e27450.

Continued

Version 2.2021, 06/17/21 © National Comprehensive Cancer Network, Inc. 2021. All rights reserved. The NCCN Guidelines® and this illustration may not be reproduced in any form without the express written permission of NCCN.

WILMS-G  
1 OF 2

that express 1 q gain or combined LOH at 1p and 16q. Whole lung irradiation is recommended for all patients who present with pulmonary metastases, with the exception of those patients with complete response of pulmonary lesions at 6 weeks, that also do not have either combined LOH of 1p and 15q, 1q gain, or other extrapulmonary metastases.

### Initially Unresectable Unilateral Renal Tumor With No Predisposing Condition

#### Clinical Trial Data

Clinical trial data from NWT5-5, AREN0532, and AREN0533 are used to support the NCCN recommendations for children with unilateral renal tumors that are initially unresectable if there are no predisposing conditions. Details about these trials and regimen M are provided in the previous section (see "Standard Risk and Higher Risk," page 962). Neoadjuvant therapy is selected using recommendations for local stage III disease.

#### NCCN Recommendations

Neoadjuvant therapy with DD4A is recommended for children with unilateral renal tumors that are initially

unresectable if there are no predisposing conditions.<sup>90,105</sup> Upfront biopsy with delayed nephrectomy should be limited to specific settings where upfront nephrectomy is contraindicated, such as patients with an inferior vena cava (IVC) thrombus above the level of the hepatic veins. Upfront biopsy is recommended for all patients meeting the criteria for delayed resection, to determine histology, establish a diagnosis of WT, and obtain molecular biomarkers to guide therapy. At week 6 of DD4A, the tumor is reimaged and depending on the tumor response, patients have either nephrectomy with regional lymph node sampling or continue with DD4A. Chemotherapy is continued for a total of 12 weeks if the patient has some response at week 6 but is not deemed a candidate for surgery. However, surgery is recommended for all patients at a maximum of week 12 of neoadjuvant chemotherapy based on clinical trial data showing that continuing chemotherapy beyond 12 weeks usually does not yield continued tumor shrinkage.<sup>70,95</sup>

After pathology confirms that patients have FHWT, molecular and imaging results are used to determine the final risk assessment and to select further therapy. Patients either continue regimen DD4A or switch to regimen M, depending on the risk assessment. Augmented therapy with regimen M is recommended for patients who are at

## PRINCIPLES OF CHEMOTHERAPY

**Dose Modifications**

- Infants do not tolerate chemotherapy drugs that have been dosed based on body surface area (BSA). Dosing based on body weight rather than BSA using the 30-Rule (BSA dose divided by 30 and multiplied by the body weight) is better tolerated. Recently, a uniform method of infant dosing of chemotherapy drugs was devised and implemented using BSA-banded infant dosing tables for patients with a BSA <0.6 m<sup>2</sup>.<sup>7</sup>
- For 6 weeks after whole lung or whole abdomen radiation, the doses of dactinomycin and doxorubicin should be reduced by 50% to ameliorate radiation recall reactions.

**Supportive Care**

- If the planned cumulative dose of doxorubicin will exceed 150 mg/m<sup>2</sup>, dexrazoxane should be administered prior to each dose of doxorubicin to ameliorate cardiotoxicity. Dexrazoxane dosing is given as a 10:1 dose ratio of dexrazoxane:doxorubicin.
- Colony-stimulating factors (filgrastim or pegfilgrastim)<sup>a</sup> are not necessary after doses of myelosuppressive agents in Regimens EE4A, DD4A, and VAD, but should be considered for courses of cyclophosphamide and etoposide and cyclophosphamide, doxorubicin, and vincristine in Regimen M and Regimen I.

**Treatment Augmentation**

- Treatment was augmented from Regimen DD4A to Regimen M at week 7 of therapy on the most recent series of Children's Oncology Group (COG) FHWT clinical trials for:
  - ▶ Patients with stage III or IV FHWT with LOH at 1p and 16q
  - ▶ Patients with stage IV FHWT and lung metastases only who did not achieve a CR after 6 weeks of Regimen DD4A
  - ▶ Patients with stage IV FHWT and extrapulmonary metastases
- Regimen M includes IV courses of cyclophosphamide and etoposide, which significantly increase the risk of infertility and secondary leukemia.
- Event-free survival for patients with stage III or IV tumors that express LOH at 1p and 16q treated with Regimen M was improved compared to a historical control group from NWTS-5, but the stage distribution differed between the two groups and overall survival was not significantly better with Regimen M.
- Event-free survival for patients with stage IV FHWT and lung metastases only who did not achieve a CR of the lung metastases after 6 weeks of Regimen DD4A on AREN0533 was improved compared to the NWTS-5 historical control, but questions have been raised about the comparability of the control group.
- Results from treating patients with stage IV FHWT and extrapulmonary metastases with Regimen M have not been published.
- Treatment was augmented from neoadjuvant VAD or EE4A to Regimen I at week 7 of therapy on COG trial AREN0534 for blastemal predominant histology in the post-neoadjuvant resected specimen based on the higher risk of relapse with this histology in European clinical trials.<sup>8</sup>

<sup>7</sup> Balis FM, Womer RB, Berg S, et al. Dosing anticancer drugs in infants: Current approach and recommendations from the Children's Oncology Group's Chemotherapy Standardization Task Force. *Pediatr Blood Cancer* 2017;64:e26636.

<sup>8</sup> van den Heuvel-Eibrink MM, van Tinteren H, Bergeron C, et al. Outcome of localised blastemal-type Wilms tumour patients treated according to intensified treatment in the SIOP WT 2001 protocol, a report of the SIOP Renal Tumour Study Group (SIOP-RTSG). *Eur J Cancer* 2015;51:498-506.

<sup>a</sup> An FDA-approved biosimilar is an appropriate substitute for filgrastim and pegfilgrastim.

Version 2.2021, 06/17/21 © National Comprehensive Cancer Network, Inc. 2021. All rights reserved. The NCCN Guidelines® and this illustration may not be reproduced in any form without the express written permission of NCCN.

WILMS-G  
2 OF 2

increased risk, including those with (1) combined LOH at 1p and 16q, or (2) metastases only in the lung that have slow incomplete response to neoadjuvant chemotherapy. Although patients with extrapulmonary metastases were switched to regimen M in a recent study (AREN0533), the results have not been published yet; therefore, regimen M is not currently recommended in this setting. Postoperative flank RT or WAI is recommended for patients with local stage III disease. Whole lung irradiation is recommended in patients whose lung metastases have not responded to 6 weeks of neoadjuvant chemotherapy, patients whose tumor expresses 1q gain or combined LOH at 1p and 16q, and patients with lung and extrapulmonary metastases. If RT is being considered, the timing of RT should be coordinated with chemotherapy to avoid the coadministration of full doses of dactinomycin or doxorubicin with RT.

### Localized Unilateral Renal Tumor With a Predisposing Condition

#### Clinical Trial Data

The AREN0534 trial assessed neoadjuvant therapy with EE4A (or VAD if an upfront biopsy was done) for 6 weeks

followed by either surgery or continuation of EE4A (or VAD) for an additional 6 weeks in 34 evaluable children who had localized unilateral renal tumor and who were predisposed to develop metachronous disease because of hemihyperplasia or a genetic predisposition syndrome, such as Beckwith-Wiedemann syndrome; the trial also included children with multiple renal tumors in one kidney (multicentric) and with unilateral renal tumor and contralateral nephrogenic rest(s) (of any size) in children younger than 12 months of age.<sup>114</sup> This trial also assessed treatment in children with metastatic unilateral WT and bilateral WT (see "Metastatic Unilateral Renal Tumor With a Predisposing Condition," page 969 and "Bilateral Renal Tumors," page 970). Patients with localized unilateral renal tumor received neoadjuvant therapy with VAD if an upfront biopsy showed FHWT.

Goals of AREN0534 included performing surgery by week 12, improving the event-free survival (compared with NWTS-5), and decreasing the need for total nephrectomy by using NSS to preserve as much renal function as possible, because these children are at risk for end-stage renal failure.<sup>114</sup> Surgery was done after either 6 weeks or 12 weeks of neoadjuvant chemotherapy based on the response at 6 weeks; continuing chemotherapy beyond

## PRINCIPLES OF RADIATION THERAPY FOR FHWT

- Consulting a radiation oncologist is recommended at time of diagnosis of WT.

**Radiotherapy Timing**

- RT should be started by day 10 after surgery (preferred) but no later than day 14, if surgery is designated day 0. A later radiation start is linked to increased risk of abdominal recurrence in some studies.<sup>1-3</sup>

**Flank Radiation**

- **Indications:** Flank RT for patients diagnosed with either local stage III or stage IV with local stage III.<sup>4</sup> See ST-1 for staging criteria. Local stage III refers to staging at the primary tumor regardless of metastases.
- **Target volume:** Contour the preoperative tumor on presentation imaging (either CT or MRI). Add a 1-cm clinical target volume (CTV) expansion. If this target would create a dose gradient along the vertebral body, contour the adjacent vertebral bodies. Add a 5- to 10-mm planning target volume (PTV) margin.
- **Flank + Para-aortic nodal volume:** Traditional para-aortic fields include the entire chain from the crus of the diaphragm to the bottom of L5. CTV should include all enlarged nodes on preoperative imaging. Add a 5- to 10-mm PTV margin.
  - **Indication:** If positive LNs are found and resected
- **Delivery of RT is recommended with photons for flank, whole abdomen, and whole lung. Boost modality should be more conformal with three-dimensional conformal RT (3D-CRT), intensity-modulated RT (IMRT), or protons.**
- Testicular shielding should be used for most boys.

**Whole Abdominal Irradiation (WAI)**

- **Indications:** Cytology-positive ascites; any preoperative tumor rupture including retroperitoneal; peritoneal seeding; and diffuse surgical spillage. See ST-1 for staging criteria.
- **Target volume:** The treatment field design shall encompass the entire peritoneal cavity that includes the dome of the diaphragm superiorly and extends inferiorly to the pelvic diaphragm (consider 4D-CT to evaluate extent of CTV motion and excursion)
- **Borders:**
  - **Superior:** 1 cm above dome of diaphragm
  - **Inferior:** Bottom of obturator foramen (femoral heads should be blocked)
  - **Lateral:** 1 cm beyond lateral abdominal walls

Continued  
References

Version 2.2021, 06/17/21 © National Comprehensive Cancer Network, Inc. 2021. All rights reserved.  
The NCCN Guidelines® and this illustration may not be reproduced in any form without the express written permission of NCCN.

WILMS-H  
1 OF 3

12 weeks usually does not yield continued tumor shrinkage.<sup>70,95</sup> If there was a less than partial response at week 6, a total nephrectomy was performed before continuing chemotherapy based upon histology. Of the 32 patients who underwent surgery, 15 had surgery at week 6 and 17 had surgery at week 12. Open renal biopsy can be done to determine the histology—FHWT or WT without evidence of anaplasia—before continuing with neoadjuvant chemotherapy. By 12 weeks of neoadjuvant chemotherapy, most patients had a partial response (62% [21/34]) or stable disease (32% [11/34]); 2 patients had a complete response; there was no progressive disease. Surgery included partial or total nephrectomy with regional lymph node sampling followed by determination of the pathology. A total nephrectomy was done if patients had a less than partial response to neoadjuvant chemotherapy at week 6. Partial nephrectomies were done in 63% (20/32) of patients.

After surgery, risk assessment was completed using histology results and stage to select further therapy including adjuvant chemotherapy with or without RT.<sup>114</sup> Use of molecular biomarkers to direct therapy was not included in AREN0534; however, outcomes were excellent despite not augmenting chemotherapy

for the presence of unfavorable biomarkers. The 4-year event-free survival was 94% (95% CI, 85.2%–100%) and the 4-year overall survival was 100%. Patients with stage I or II FHWT without blastemal-predominant histology are at lower risk of relapse after surgery; therefore, they continued receiving less intensive adjuvant therapy with EE4A and did not receive adjuvant RT.<sup>114</sup> Patients with blastemal-predominant histology following neoadjuvant chemotherapy are at greater risk of relapse after surgery; therefore, they switched to more intensive adjuvant therapy with DD4A or regimen I, depending on the stage.<sup>114,122</sup>

**NCCN Recommendations**

Neoadjuvant therapy with the EE4A regimen is recommended for children with a localized unilateral renal tumor and a predisposing condition.<sup>51,114,123</sup> Upfront biopsy or resection is discouraged in this setting. However, if an upfront biopsy was done, then the VAD regimen is used as neoadjuvant therapy. At week 6 of EE4A (or VAD), the tumor is reimaged and depending on the response, patients (1) have no surgery if there was a complete response to EE4A (or VAD); (2) have partial nephrectomy with regional lymph node sampling if the tumor is

## PRINCIPLES OF RADIATION FOR FHWT (CONTINUED)

**Supplemental, "Boost" Irradiation**

- Indications: Supplemental irradiation is required after flank or WAI for gross residual tumor.
- Treatment technique: Conformal techniques are preferred (3D-CRT, IMRT, or protons)
- Target volume: 3D imaging data should be acquired with the patient in the treatment position to define a gross tumor volume (GTV), CTV, PTV, and critical structures. 4D imaging should be considered.
  - ▶ GTV is the postoperative residual tumor and should be based on imaging performed for treatment planning and postoperative diagnostic CT/MRI.
  - ▶ CTV will be an anatomically confined margin of 0.5 cm surrounding the GTV.
  - ▶ PTV will be a geometrically expanded margin surrounding the CTV. The PTV margin will be chosen by the local institution, ranging from 0.5–1 cm.

**Whole Lung Irradiation**

- Indications: Lung metastases. Whole lung irradiation can be delayed to week 6 in select patients with FHWT who only have metastases in the lungs. If there is a CR to chemotherapy, then whole lung irradiation can be omitted.
- Target volume: The CTV is the entire pleural surface of lung on CT simulation. Add a 5- to 10-mm PTV.
- Technique: Anteroposterior/posteroanterior (AP/PA) or IMRT<sup>5-7</sup>
- If treating whole lung and abdomen/flank, consider using one large field to avoid match lines.

**Radiation Doses**

- Flank (10.8 Gy) for local stage III
- Whole abdomen (10.5 Gy)
  - ▶ Tumor rupture
  - ▶ Surgical spill
  - ▶ Peritoneal implants
- Whole lung (12 Gy or 10.5 Gy if <12 mo)
- LN irradiation. 10.8 Gy for resected LN metastases and 19.8 Gy for unresected LN metastases.

**Gross Residual Tumor**

- Boost irradiation 10.8 Gy in 6 fx for a total dose of 21.6 Gy

## References

WILMS-H  
2 OF 3

Version 2.2021, 06/17/21 © National Comprehensive Cancer Network, Inc. 2021. All rights reserved. The NCCN Guidelines® and this illustration may not be reproduced in any form without the express written permission of NCCN.

now resectable; (3) continue with EE4A (or VAD) for a total of 12 weeks if the tumor is still unresectable but shows at least a partial response; or (4) have complete nephrectomy for those with less than a partial response. If there is a less than partial response at week 6, the tumor should be biopsied to confirm a diagnosis of FHWT (or WT without evidence of anaplasia) before continuing with EE4A (or VAD). Surgery is done at 12 weeks after neoadjuvant chemotherapy based on data showing that continuing chemotherapy beyond 12 weeks usually does not yield continued tumor shrinkage.<sup>70,95</sup> A partial or total nephrectomy with regional lymph node sampling is recommended at week 12.<sup>61</sup> The decision to do a partial versus total nephrectomy is based on tumor size, location in the kidney, extension into the kidney collecting system, and other factors.

The only setting where NCCN recommendations are based on SIOP guidelines is the management of unilateral, initially unresectable tumors where COG has borrowed from SIOP data regarding the recommendation to change chemotherapy if histology is blastemal predominant at delayed nephrectomy. After pathology confirms that patients have FHWT, histology (ie, blastemal predominant) and staging are used to select further therapy (see “Children’s Oncology Group (COG) Staging of Wilms

Tumor,” available in these guidelines at NCCN.org). If upfront biopsy was done and patients received VAD, the tumor is considered to be stage III for determining the adjuvant chemotherapy regimen. Patients either continue regimen EE4A, switch to regimen DD4A, or switch to regimen I, depending on the risk assessment. If patients have a complete response at 6 weeks to regimen EE4A, then they continue EE4A and do not receive RT.<sup>114</sup> Switching to regimen DD4A is recommended for patients who are at increased risk, including those with (1) stage III FHWT without blastemal predominant histology; or (2) stage I FHWT with blastemal predominant histology. Augmented therapy with regimen I is recommended for patients with blastemal predominant histology and stage II or III FHWT, because they are at the greatest risk. Regimen M has not been studied in this population. RT is often given 10 to 14 days after surgery; the patient’s age and other factors are considered when deciding about the timing of RT. Local stage III refers to the staging at the primary tumor, regardless of metastases, and is used to determine the need for flank RT or WAI (see “Principles of Radiation Therapy for FHWT” [WILMS-H] in the algorithm). Neoadjuvant chemotherapy is not a criterion for upstaging to stage III in this setting. Biopsy alone in this situation



**PRINCIPLES OF RADIATION FOR FHWT  
REFERENCES**

- <sup>1</sup> D'Angio GJ, Tefft M, Breslow N, Meyer JA. Radiation therapy of Wilms' tumor: Results according to dose, field, post-operative timing and histology. *Int J Radiat Oncol Biol Phys* 1978;4:769-780.
- <sup>2</sup> Kalapurakal JA, Li SM, Breslow NE, et al; National Wilms' Tumor Study Group. Influence of radiation therapy delay on abdominal tumor recurrence in patients with favorable histology Wilms' tumor treated on NWTS-3 and NWTS-4: a report from the National Wilms' Tumor Study Group. *Int J Radiat Oncol Biol Phys* 2003;57:495-499.
- <sup>3</sup> Stokes CL, Stokes WA, Kalapurakal JA, et al. Timing of radiation therapy in pediatric Wilms tumor: a report from the National Cancer Database. *Int J Radiat Oncol Biol Phys* 2018;101:453-461.
- <sup>4</sup> Hua C-H, Vern-Gross TZ, Hess CB, et al. Practice patterns and recommendations for pediatric image-guided radiotherapy: A Children's Oncology Group report. *Pediatr Blood Cancer* 2020;67:e28629.
- <sup>5</sup> Kalapurakal JA, Lee B, Bautista J, et al. Cardiac-sparing whole lung intensity modulated radiation therapy in children with Wilms Tumor. Final report on technique and abdominal field matching to maximize normal tissue protection. *Pract Radiat Oncol* 2019;9:e62-e73.
- <sup>6</sup> Kalapurakal JA, Zhang Y, Kepka A, et al. Cardiac-sparing whole lung IMRT in children with lung metastasis. *Int J Radiat Oncol Biol Phys* 2013;85:761-767.
- <sup>7</sup> Kalapurakal JA, Gopalakrishnan M, Walterhouse DO, et al. Cardiac-sparing whole lung IMRT in patients with pediatric tumors and lung metastasis: final report of a prospective multicenter clinical trial. *Int J Radiat Oncol Biol Phys* 2019;103:28-37.

Version 2.2021, 06/17/21 © National Comprehensive Cancer Network, Inc. 2021. All rights reserved.  
The NCCN Guidelines® and this illustration may not be reproduced in any form without the express written permission of NCCN.

**WILMS-H  
3 OF 3**

does not upstage a tumor to stage III for determining whether to give RT.

### Metastatic Unilateral Renal Tumor With a Predisposing Condition

#### **Clinical Trial Data**

The AREN0534 study assessed neoadjuvant therapy with VAD for 6 weeks followed by either surgery or continuation of VAD for an additional 6 weeks in children who had metastatic unilateral renal tumor and who were predisposed to develop metachronous bilateral disease because of hemihyperplasia or a genetic syndrome, such as Beckwith-Wiedemann syndrome.<sup>51,114,123</sup> One of the 32 patients who underwent surgery had stage IV disease. This trial also assessed treatment in children with localized unilateral WT and bilateral WT (see “Localized Unilateral Renal Tumor With a Predisposing Condition,” page 966 and “Bilateral Renal Tumors,” page 970). Additional details about AREN0534 are provided in the previous section (see “Localized Unilateral Renal Tumor With a Predisposing Condition,” page 966).

After surgery, risk assessment was done using histology results and stage to select adjuvant therapy, including RT.<sup>114</sup> Use of molecular biomarkers to direct therapy was not

included on AREN0534; however, outcomes were excellent despite not augmenting chemotherapy for the presence of unfavorable biomarkers. Patients without blastemal histology are at lower risk of relapse after surgery; therefore, they switched from VAD to adjuvant therapy with DD4A and adjuvant RT for local stage 3 disease.<sup>114</sup> Patients with blastemal histology after neoadjuvant chemotherapy are at greater risk of relapse after surgery; therefore, they switched to more intensive adjuvant therapy with regimen I and adjuvant RT for local stage 3 disease.<sup>114,122</sup>

#### **NCCN Recommendations**

Neoadjuvant therapy with the VAD regimen is recommended for children with a predisposing condition and a unilateral renal tumor that has metastasized.<sup>114</sup> Upfront biopsy or resection is discouraged in this setting. At week 6 of VAD, the tumor is reimaged and depending on the response, patients (1) have no surgery if there was a complete response to VAD; (2) have partial nephrectomy at week 6 if the tumor is now resectable; or (3) continue with VAD for a total of 12 weeks if the tumor is unresectable but shows at least a partial response. If there is a less than partial response at week 6, the tumor should be biopsied to confirm a diagnosis of FHWT (or WT without

## SYNDROMES AND CONGENITAL ANOMALIES ASSOCIATED WITH WILMS TUMOR

**Somatic Genetic Variants**

- Most common somatic variants in WT are:
  - ▶ *CTNNB1*, *DROSHA*, *WT1*, *WTX*, *WTX (AMER-1)*, *DGCR8*, *SIX1*, *BCORL1*, *MLLT1*, *MYCN*, *SIX2*; *TP53* is associated with anaplastic WT<sup>1</sup>
  - ▶ *WT1*, a tumor suppressor gene found on chromosome 11p13, is implicated in the development of WT. *WT1* codes a transcription factor crucial for normal kidney/genitourinary function (5%–10% of cases)<sup>2-11</sup>
  - ▶ *WT2*, a tumor suppressor gene found on chromosome 11p15, is also implicated in the development of WT.
- WT predisposition genes by exome sequencing<sup>1,12-13</sup>
  - ▶ *REST*, *TRIM28*, *FBXW7*, *NYNRIN*, *KDM3B*, *XPO5*, *CHEK2*, and *PALB2*
- Predisposition syndromes associated with WT<sup>14</sup>
  - ▶ Denys-Drash syndrome<sup>15,16</sup> (MIM: 607102):
    - Inheritance autosomal dominant (AD)
    - Gene *WT1*; locus 11p13
    - Disorders of sexual development (DSD), mesangial sclerosis, renal failure, usually 46 XY karyotype<sup>17</sup>
  - ▶ Frasier syndrome<sup>18</sup> (MIM: 607102)
    - Inheritance AD
    - Gene *WT1*; locus 11p13
    - DSD, progressive glomerular nephropathy, patients present with normal female external genitalia, streak gonads, and XY karyotype, and frequently develop gonadoblastoma
  - ▶ Beckwith-Wiedemann syndrome<sup>19-20</sup> (MIM: 616186, 604115, 600856):
    - Inheritance complex: AD, uniparental disomy, epimutations involving locus 11p15.5
    - Characterized by gigantism, omphalocele, macroglossia, genitourinary abnormalities, ear pits and creases, hypoglycemia, and hemihyperplasia; present in about 5% of children with WT.<sup>21-22</sup>
  - ▶ Contiguous gene deletion syndrome or WAGR/WAGR syndrome with obesity (WAGRO)<sup>23</sup> (MIM 194072, 612469)
    - Gene *WT1* gene; locus 11p13
    - Characterized by aniridia, genitourinary abnormalities, obesity, and hemihyperplasia;
  - ▶ Trisomy 18 syndrome<sup>24</sup>
- Other syndromes
  - ▶ Li Fraumeni syndrome<sup>25</sup> (MIM: 191170)
    - Inheritance AD
    - Gene *TP53*
    - Broad cancer predisposition syndrome associated with anaplastic Wilms tumor in young patients.

## References

WILMS-I  
1 OF 3

Version 2.2021, 06/17/21 © National Comprehensive Cancer Network, Inc. 2021. All rights reserved.  
The NCCN Guidelines® and this illustration may not be reproduced in any form without the express written permission of NCCN.

evidence of anaplasia) before continuing with VAD. Surgery is done at 12 weeks after neoadjuvant chemotherapy based on data showing that continuing chemotherapy beyond 12 weeks usually does not yield continued tumor shrinkage.<sup>70,95</sup> A partial or total nephrectomy with regional lymph node sampling is recommended at week 12. The decision to do a partial versus total nephrectomy is based on tumor size, location in the kidney, extension into the kidney collecting system, and other factors.

After pathology confirms that patients have FHWT, histology (ie, blastemal predominant) is used to select further therapy. Use of molecular biomarkers to direct therapy has not been studied in this setting; outcomes on AREN0534 were excellent despite not augmenting chemotherapy for the presence of unfavorable biomarkers. Patients either switch to regimen DD4A or switch to regimen I, depending on the risk assessment. Switching to regimen DD4A is recommended for patients without blastemal predominant histology or those with a complete response at 6 weeks. Augmented therapy with regimen I is recommended for patients with blastemal predominant histology because they are at greater risk. Regimen M has not been studied in this population. RT is often given 10

to 14 days after surgery; the patient's age and other factors are considered when deciding about the timing of RT. Local stage III refers to the staging at the primary tumor, regardless of metastases, and is used to determine the need for flank RT or WAI (see "Principles of Radiation Therapy for FHWT" [WILMS-H] in the algorithm). Biopsy alone does not upstage a tumor to stage III for determining whether to give RT. Neoadjuvant chemotherapy is not a criterion for upstaging to stage III in this setting. Omission of whole lung irradiation based on the response of lung metastases at week 6 of neoadjuvant chemotherapy has not been studied in this group of patients.

**Bilateral Renal Tumors**

Children with bilateral WT have a greater incidence of predisposition syndromes and a greater risk for developing a metachronous tumor after treatment, probably because of an increased incidence of nephrogenic rests.<sup>15,39,114</sup> Children who present at a younger age are more likely to have multifocal/bilateral disease and their tumors are often identified as part of a surveillance program.<sup>16,51</sup> When compared with unilateral WT, children with bilateral WT have decreased survival because of understaging and increased incidence of anaplastic histology.<sup>61</sup> The

## SYNDROMES AND CONGENITAL ANOMALIES ASSOCIATED WITH WILMS TUMOR

- Other syndromes (cont.)
    - ▶ Perlman syndrome<sup>26</sup> (MIM: 614184):
      - Inheritance autosomal recessive (AR)
      - Gene *DIS3L2*
      - Affected children are large at birth, are hypotonic, and show organomegaly, characteristic facial dysmorphisms (inverted V-shaped upper lip, prominent forehead, deep-set eyes, broad and flat nasal bridge, and low-set ears), renal anomalies (nephromegaly and hydronephrosis), frequent neurodevelopmental delay, and high neonatal mortality.
    - ▶ Bohring-Optiz syndrome<sup>27-28</sup> (MIM: 605039)
      - Inheritance AD
      - Gene *ASXL1*
      - Malformation syndrome characterized by severe intrauterine growth retardation, poor feeding, profound mental retardation, trigonocephaly, prominent metopic suture, exophthalmos, nevus flammeus of the face, upslanting palpebral fissures, hirsutism, and flexion of the elbow and wrists with deviation of the wrists and metacarpophalangeal joints
    - ▶ MULIBREY (MUscle, LIver, BRain, and EYes) Nanism syndrome<sup>29</sup> (MIM: 605073, <https://omim.org/entry/253250>)
      - Inheritance AR
      - Gene *TRIM37*
      - Growth disorder with prenatal onset, including occasional progressive cardiomyopathy, characteristic facial features, failure of sexual maturation, insulin resistance with type 2 diabetes, and an increased risk for Wilms tumor
  - Congenital anomalies associated with predisposition syndromes
    - ▶ Aniridia
    - ▶ Cryptorchidism
    - ▶ Hemihyperplasia
    - ▶ Horseshoe kidney (patients are twice as likely to develop WT)
    - ▶ Hypospadias
    - ▶ Renal duplication
    - ▶ Renal ectopia
    - ▶ Renal hypoplasia
    - ▶ Mesoblastic nephroma
    - ▶ Ureteral duplication
  - Surveillance recommendations for WT predisposition syndromes<sup>10,14</sup>
    - ▶ The Pediatric Cancer Working Group of the American Association for Cancer Research recommends renal US every 3 mo up to age 8 y
- Familial Nephroblastoma**
- *FWT1/FWT2* (Familial WT) gene mutations account for about 1%–2% of WT cases. These mutations are autosomal dominant with variable penetrance. They have no association with the *WT1* mutation. *FWT1* is found on chromosome 17q, whereas *FWT2* is found on chromosome 19q.<sup>21,30-32</sup>

References

Version 2.2021, 06/17/21 © National Comprehensive Cancer Network, Inc. 2021. All rights reserved.  
The NCCN Guidelines® and this illustration may not be reproduced in any form without the express written permission of NCCN.

WILMS-I  
2 OF 3

treatment goal for children with bilateral WT is to improve survival and preserve as much renal function as possible by using less intensive chemotherapy and NSS, if feasible. Unfortunately, the incidence of end-stage renal disease is higher (12%) in children with bilateral WT compared with unilateral WT (0.6%).<sup>20,124</sup> In patients with small lesions suspicious for bilateral WT, it may be difficult to distinguish nephrogenic rests from WT using imaging and percutaneous biopsies; MRI may be useful in this setting.

### Clinical Trial Data

The AREN0534 trial assessed neoadjuvant therapy with VAD for 6 weeks followed by either surgery or continuation of VAD for an additional 6 weeks in 189 evaluable children with bilateral FHWT.<sup>61</sup> This trial also assessed treatment in children with unilateral WT and a predisposing syndrome (see “Unilateral Renal Tumors,” page 960). Goals of AREN0534 included performing surgery by week 12, improving the event-free survival (compared with NWTS-5), and decreasing the need for total nephrectomy by using NSS, if feasible, to preserve renal function. Surgery was done at either 6 weeks or 12 weeks after neoadjuvant chemotherapy based on the response at 6 weeks;

continuing chemotherapy beyond 12 weeks usually does not yield continued tumor shrinkage.<sup>70,95</sup> If there was a less than partial response at week 6, open renal biopsies in both kidneys were done to determine the histology—FHWT or WT without evidence of anaplasia—before continuing with VAD. However, bilateral renal tumors in children that are not WT are very uncommon. By 12 weeks, most patients had a partial response to neoadjuvant chemotherapy. Surgery was done with the goal of preserving as much renal function as possible, if feasible, and included (1) a partial nephrectomy on one or both sides; or (2) a total nephrectomy with regional lymph node sampling and a contralateral partial nephrectomy on one side. Data show that use of partial nephrectomy preserves renal function in patients with bilateral WT.<sup>125</sup> Most patients (84%) had had surgery by 12 weeks; 61% of patients needed a complete nephrectomy in at least one kidney.

Histology results and stage were used to select further therapy including RT and/or adjuvant chemotherapy. To determine adjuvant therapy, risk assessment was done using the kidney with the highest stage. Patients with complete necrosis after neoadjuvant chemotherapy or with stage I FHWT without blastemal-predominant histology are at lower risk of relapse after surgery; therefore, they

SYNDROMES AND CONGENITAL ANOMALIES ASSOCIATED WITH WILMS TUMOR  
REFERENCES

- 1 Gadd S, Huff V, Walz AL, et al. A children's oncology group and TARGET initiative exploring the genetic landscape of Wilms tumor. *Nat Genet* 2017;49:1487-1494.
- 2 Riccardi VM, Hittner HM, Francke U, et al. The aniridia-Wilms' tumor association: The critical role of chromosome band 11p13. *Cancer Genet* 1980;2:131-137.
- 3 Palmer N, Evans AE. The association of aniridia and Wilms' tumor: methods of surveillance and diagnosis. *Med Pediatr Oncol* 1983;11:73-75.
- 4 Pendergrass TW. Congenital anomalies in children with Wilms' tumor: a new survey. *Cancer* 1976;37:403-408.
- 5 Breslow NE, Beckwith JB. Epidemiological features of Wilms' tumor: results of the National Wilms' Tumor Study. *J Natl Cancer Inst* 1982;68:429-436.
- 6 Gutjahr P. Progress and controversies in modern treatment of Wilms' tumor. *World J Urol* 1995;13:209-212.
- 7 Charlton J, Irtan S, Bergeron C, et al. Bilateral Wilms tumour: a review of clinical and molecular features. *Expert Rev Mol Med* 2017;19:e8.
- 8 Gadd S, Huff V, Huang CC, et al. Clinically relevant subsets identified by gene expression patterns support a revised ontogenic model of Wilms tumor: a Children's Oncology Group study. *Neoplasia* 2012;14:742-756.
- 9 Gessler M, Poutska A, Cavenee W, et al. Homozygous deletion in Wilms' tumors of zinc-finger gene identified by chromosome jumping. *Nature* 1990;343:774-778.
- 10 Bonetta L, Kuetin SE, Huang A, et al. Wilms' tumor locus on 11p13 defined by multiple CpG island-associated transcripts. *Science* 1990;250:994-997.
- 11 Srinivasan AS, Saade-Lemus S, Servaes SE, et al. Imaging surveillance for children with predisposition to renal tumors. *Pediatr Radiol* 2019;49:1453-1462.
- 12 Mahamdallie SS, Hanks S, Karlin KL, et al. Mutations in the transcriptional repressor REST predispose to Wilms tumor. *Nat Genet*. 2015;47:1471-1474. Erratum in: *Nat Genet* 2016;48:473.
- 13 Mahamdallie S, Yost S, Poyastro-Pearson E, et al. Identification of new Wilms tumour predisposition genes: an exome sequencing study. *Lancet Child Adolesc Health* 2019;3:322-331.
- 14 Kalish JM, Doros L, Helman LJ, et al. Surveillance recommendations for children with overgrowth syndromes and predisposition to Wilms tumors and hepatoblastoma. *Clin Cancer Res* 2017;23:e115-e122.
- 15 Hillen LM, Kamsteeg EJ, Schoots J, et al. Refining the diagnosis of congenital nephrotic syndrome on long-term stored tissue: c.1097G>A (p.(Arg366His)) WT1 mutation causing Denys Drash Syndrome. *Fetal Pediatr Pathol* 2016;35:112-119.
- 16 Heathcote RW, Morison IM, Gubler MC, et al. A review of the phenotypic variation due to the Denys-Drash syndrome-associated germline WT1 mutation R362X. *Hum Mutat* 2002;19:462.
- 17 Breslow NE, Collins AJ, Ritchey ML, et al. End stage renal disease in patients with Wilms tumor: results from the National Wilms Tumor Study Group and the United States Renal Data System. *J Urol* 2005;174:1972-1975.
- 18 Barbaux S, Naudet P, Gubler MC, et al. Donor splice-site mutations in WT1 are responsible for Frasier syndrome. *Nat Genet* 1997;17:467-470.
- 19 Wang KH, Kupa J, Duffy KA, Kalish JM. Diagnosis and management of Beckwith-Wiedemann syndrome. *Front Pediatr* 2020;7:562.
- 20 Fiala EM, Ortiz MV, Kennedy JA, et al. 11p15.5 epimutations in children with Wilms tumor and hepatoblastoma detected in peripheral blood. *Cancer* 2020;126:3114-3121.
- 21 Koufos A, Grundy P, Morgan K, et al. Familial Wiedemann-Beckwith syndrome to 11p15.5. *Am J Hum Genet* 1989;44:711-719.
- 22 Ping AJ, Reeve AE, Law DJ, et al. Genetic linkage of Beckwith-Wiedemann syndrome to 11p15. *Am J Hum Genet* 1989;44:720-723.
- 23 Han JC, Liu QR, Jones M, et al. Brain-derived neurotrophic factor and obesity in the WAGR syndrome. *N Engl J Med*. 2008;359:918-927. Erratum in: *N Engl J Med* 2008;359:1414.
- 24 Sergi C, Kos M. Bilateral Wilms' tumor in Trisomy 18 syndrome: Case report and critical review of the literature. *Ann Clin Lab Sci* 2018;48:369-372.
- 25 Oh L, Hafs H, Hainaut P, Ariffin H. p53, stem cell biology and childhood blastomas. *Curr Opin Oncol* 2019;31:84-91.
- 26 Astuti D, Morris MR, Cooper WN, et al. Germline mutations in DIS3L2 cause the Perlman syndrome of overgrowth and Wilms tumor susceptibility. *Nat Genet* 2012;44:277-284.
- 27 Russell B, Tan WH, Graham JM Jr. Bohring-Opitz Syndrome. 2018 Feb 15. In: Adam MP, Ardinger HH, Pagon RA, et al., editors. *GeneReviews*® [Internet]. Seattle (WA): University of Washington, Seattle; 1993-2021. Available from: <https://www.ncbi.nlm.nih.gov/books/NBK481833/>.
- 28 Hoischen A, van Bon BW, Rodriguez-Santiago B, et al. De novo nonsense mutations in ASXL1 cause Bohring-Opitz syndrome. *Nat Genet* 2011;43:729-731.
- 29 Hämläinen RH, Mowat D, Gabbett MT, et al. Wilms' tumor and novel TRIM37 mutations in an Australian patient with mulibrey nanism. *Clin Genet* 2006;70:473-479.
- 30 Grundy P, Koufos A, Morgan K, et al. Familial predisposition to Wilms' tumour does not map to the short arm of chromosome 11. *Nature* 1988;336:374-376.
- 31 Rahman N, Arbour L, Tonin P, et al. Evidence for a familial Wilms' tumour gene (FWT1) on chromosome 17q12-q21. *Nat Genet* 1996;13:461-463.
- 32 McDonald JM, Douglass EC, Fisher R, et al. Linkage of familial Wilms' tumor predisposition to chromosome 19 and a two-locus model for the etiology of familial tumors. *Cancer Res* 1998;58:1387-1390.

Version 2.2021, 06/17/21 © National Comprehensive Cancer Network, Inc. 2021. All rights reserved. The NCCN Guidelines® and this illustration may not be reproduced in any form without the express written permission of NCCN.

WILMS-I  
3 OF 3

received EE4A, which is less intensive adjuvant chemotherapy. Patients with blastemal-predominant histology are at greater risk of relapse after surgery; therefore, they received more intensive adjuvant therapy.<sup>61,122</sup> For 11 children with bilateral FHWT and blastemal-predominant histology on ARE0534, the 4-year event-free survival was 81.8% (95% CI, 42.3%–100%) and the 4-year overall survival was 91% (95% CI, 64.1%–100%).<sup>61</sup> For 140 children with bilateral FHWT but without blastemal-predominant histology on ARE0534, the 4-year event-free survival was 83.18% (95% CI, 73.2%–92.96%) and the 4-year overall survival was 97.7% (95% CI, 93.90%–100%).<sup>61</sup> On the older NWTS-5 trial, 4-year event-free survival was 65% for patients with bilateral FHWT.<sup>11</sup>

### NCCN Recommendations

#### Localized Bilateral Renal Tumors With or Without a Predisposing Condition

Neoadjuvant therapy with the VAD regimen is recommended for children with localized bilateral renal tumors with or without a predisposing condition.<sup>61</sup> Upfront biopsy or resection is discouraged in this setting. Surgery is done at either 6 weeks or 12 weeks after neoadjuvant

chemotherapy based on the response; data show that continuing chemotherapy beyond 12 weeks usually does not yield continued tumor shrinkage.<sup>70,95</sup> NSS is recommended to preserve as much renal function as possible, if feasible, including (1) a partial nephrectomy on both sides; or (2) a total nephrectomy and a contralateral partial nephrectomy. In either case, regional lymph node sampling should be performed. At week 6 of VAD, the tumors are reimaged and depending on the response, patients (1) have no surgery if there was a complete response to VAD; (2) have bilateral partial nephrectomies at week 6 if the tumors are now resectable; or (3) continue with VAD for a total of 12 weeks if the tumors are still unresectable. If there is a less than partial response at week 6, renal biopsies in both kidneys are recommended to determine the histology—FHWT or WT without evidence of anaplasia—before continuing with VAD.

After pathology confirms that patients have FHWT, staging and histology (ie, blastemal predominant) are used to select further therapy. Use of molecular biomarkers to direct therapy has not been studied in this setting. Patients switch to regimen EE4A, DD4A, or regimen I, depending on the risk assessment. If a biopsy was done, a tumor is considered to be stage III for determining the

adjuvant chemotherapy regimen. Switching to regimen EE4A is recommended for patients with stage I FHWT without blastemal predominant histology, those with stage II FHWT with complete necrosis, or those with a complete response at 6 weeks of neoadjuvant chemotherapy. Switching to regimen DD4A is recommended for patients with (1) stage II or III FHWT without blastemal predominant histology; or (2) stage I FHWT with blastemal predominant histology. Augmented therapy with regimen I is recommended for patients with stage II or III FHWT with blastemal predominant histology, because they are at greatest risk.

RT is often given 10 to 14 days after surgery; the patient's age and other factors are considered when deciding about the timing of RT. Local stage III refers to the staging at the primary tumor, regardless of metastases, and is used to determine the need for flank RT or WAI (see "Principles of Radiation Therapy for FHWT" [WILMS-H] in the algorithm). Upfront biopsy does not upstage a tumor to stage III for determining whether to give RT. Neoadjuvant chemotherapy is not a criterion for upstaging to stage III in this setting. Patients with a complete response at 6 weeks of neoadjuvant chemotherapy do not need RT.

#### *Metastatic Bilateral Renal Tumors With or Without a Predisposing Condition*

Neoadjuvant therapy with the VAD regimen is recommended for children with metastatic bilateral renal tumors with or without a predisposing condition.<sup>61</sup> Upfront biopsy or resection is discouraged in this setting. At week 6 of VAD, the tumor is reimaged and depending on the response, patients (1) have no surgery if there was a complete response to VAD; (2) have partial nephrectomy at week 6 if the tumors are now resectable; or (3) continue with VAD for a total of 12 weeks if the tumors are still unresectable. If there is a less than partial response at week 6, the tumor should be biopsied

to confirm a diagnosis of FHWT (or WT without evidence of anaplasia) before continuing with VAD. Surgery is done at either 6 weeks or 12 weeks after neoadjuvant chemotherapy based on data showing that continuing chemotherapy beyond 12 weeks usually does not yield continued tumor shrinkage.<sup>70,95</sup> NSS is recommended to preserve as much renal function as possible, if feasible, including (1) a partial nephrectomy at one or both sides; or (2) a total nephrectomy and a partial nephrectomy on the contralateral side. In either case, regional lymph node sampling should be performed.

After pathology confirms that patients have FHWT, histology (ie, blastemal predominant) is used to select further therapy. Patients switch to regimen DD4A or regimen I, depending on the risk assessment. Switching to regimen DD4A is recommended for patients without blastemal predominant histology or those with a complete response at 6 weeks of neoadjuvant chemotherapy. Augmented therapy with regimen I is recommended for patients with blastemal predominant histology, because they are at greater risk. Use of molecular biomarkers to direct therapy has not been studied in this setting.

RT is often given 10 to 14 days after surgery; the patient's age and other factors are considered when deciding about the timing of RT. Local stage III refers to the staging at the primary tumor, regardless of metastases, and is used to determine the need for flank RT or WAI (see "Principles of Radiation Therapy for FHWT" [WILMS-H] in the algorithm). Upfront biopsy does not upstage a tumor to stage III for determining whether to give RT. Neoadjuvant chemotherapy is not a criterion for upstaging to stage III in this setting. Patients with a complete response at 6 weeks of neoadjuvant chemotherapy do not need RT. Whole lung irradiation is administered in patients with lung metastases, and extrapulmonary metastatic sites may also require radiation.

## References

- Howlader N, Noone AM, Krapcho M, et al. SEER Cancer Statistics Review, 1975-2018. Bethesda, MD: National Cancer Institute. Accessed July 19, 2021. Available at [https://seer.cancer.gov/csr/1975\\_2018/](https://seer.cancer.gov/csr/1975_2018/)
- Breslow N, Olshan A, Beckwith JB, et al. Epidemiology of Wilms tumor. *Med Pediatr Oncol* 1993;21:172-181.
- Steliarova-Foucher E, Colombet M, Ries LAG, et al. International incidence of childhood cancer, 2001-10: a population-based registry study. *Lancet Oncol* 2017;18:719-731.
- Breslow N, Olshan A, Beckwith JB, et al. Ethnic variation in the incidence, diagnosis, prognosis, and follow-up of children with Wilms' tumor. *J Natl Cancer Inst* 1994;86:49-51.
- Apple A, Lovvorn HN III. Wilms tumor in Sub-Saharan Africa: molecular and social determinants of a global pediatric health disparity. *Front Oncol* 2020;10:606380.
- Hadley LG, Rouma BS, Saad-Eldin Y. Challenge of pediatric oncology in Africa. *Semin Pediatr Surg* 2012;21:136-141.
- Irtan S, Ehrlich PF, Pritchard-Jones K. Wilms tumor: "state-of-the-art" update, 2016. *Semin Pediatr Surg* 2016;25:250-256.
- Gratias EJ, Dome JS, Jennings LJ, et al. Association of chromosome 1q gain with inferior survival in favorable-histology Wilms tumor: a report from the Children's Oncology Group. *J Clin Oncol* 2016;34:3189-3194.
- Dome JS, Graf N, Geller JI, et al. Advances in Wilms tumor treatment and biology: progress through international collaboration. *J Clin Oncol* 2015;33:2999-3007.
- Dome JS, Perlman EJ, Graf N. Risk stratification for Wilms tumor: current approach and future directions. *Am Soc Clin Oncol Educ Book* 2014:215-223.
- Dome JS, Cotton CA, Perlman EJ, et al. Treatment of anaplastic histology Wilms' tumor: results from the fifth National Wilms' Tumor Study. *J Clin Oncol* 2006;24:2352-2358.
- Daw NC, Chi YY, Kalapurakal JA, et al. Activity of vincristine and irinotecan in diffuse anaplastic Wilms tumor and therapy outcomes of stage II to IV disease: results of the Children's Oncology Group AREN0321 study. *J Clin Oncol* 2020;38:1558-1568.
- Maas MH, Cransberg K, van Grotel M, et al. Renin-induced hypertension in Wilms tumor patients. *Pediatr Blood Cancer* 2007;48:500-503.

14. Ehrlich PF, Ferrer FA, Ritchey ML, et al. Hepatic metastasis at diagnosis in patients with Wilms tumor is not an independent adverse prognostic factor for stage IV Wilms tumor: a report from the Children's Oncology Group/National Wilms Tumor Study Group. *Ann Surg* 2009;250:642–648.
15. Dome JS, Huff V. Wilms Tumor Predisposition. In: Adam MP, Ardinger HH, Pagon RA, eds. *GeneReviews*®. [Internet]. University of Washington, Seattle; 2003.
16. Kalish JM, Doros L, Helman LJ, et al. Surveillance recommendations for children with overgrowth syndromes and predisposition to Wilms tumors and hepatoblastoma. *Clin Cancer Res* 2017;23:e115–122.
17. Hillen LM, Kamsteeg EJ, Schoots J, et al. Refining the diagnosis of congenital nephrotic syndrome on long-term stored tissue: c.1097G>A (p.(Arg366His)) WT1 mutation causing Denys Drash syndrome. *Fetal Pediatr Pathol* 2016;35:112–119.
18. Heathcott RW, Morison IM, Gubler MC, et al. A review of the phenotypic variation due to the Denys-Drash syndrome-associated germline WT1 mutation R362X. *Hum Mutat* 2002;19:462.
19. Wang KH, Kupa J, Duffy KA, et al. Diagnosis and management of Beckwith-Wiedemann syndrome. *Front Pediatr* 2020;7:562.
20. Breslow NE, Collins AJ, Ritchey ML, et al. End stage renal disease in patients with Wilms tumor: results from the National Wilms Tumor Study Group and the United States Renal Data System. *J Urol* 2005;174:1972–1975.
21. Grundy P, Coppes M. An overview of the clinical and molecular genetics of Wilms' tumor. *Med Pediatr Oncol* 1996;27:394–397.
22. Blakely ML, Ritchey ML. Controversies in the management of Wilms' tumor. *Semin Pediatr Surg* 2001;10:127–131.
23. Douglass EC, Look AT, Webber B, et al. Hyperdiploidy and chromosomal rearrangements define the anaplastic variant of Wilms' tumor. *J Clin Oncol* 1986;4:975–981.
24. Riccardi VM, Hittner HM, Francke U, et al. The aniridia-Wilms tumor association: the critical role of chromosome band 11p13. *Cancer Genet Cytogenet* 1980;2:131–137.
25. Han JC, Liu QR, Jones M, et al. Brain-derived neurotrophic factor and obesity in the WAGR syndrome. *N Engl J Med* 2008;359:918–927.
26. Fiala EM, Ortiz MV, Kennedy JA, et al. 11p15.5 epimutations in children with Wilms tumor and hepatoblastoma detected in peripheral blood. *Cancer* 2020;126:3114–3121.
27. Ping AJ, Reeve AE, Law DJ, et al. Genetic linkage of Beckwith-Wiedemann syndrome to 11p15. *Am J Hum Genet* 1989;44:720–723.
28. Koufos A, Grundy P, Morgan K, et al. Familial Wiedemann-Beckwith syndrome and a second Wilms tumor locus both map to 11p15.5. *Am J Hum Genet* 1989;44:711–719.
29. Barboux S, Niaudet P, Gubler MC, et al. Donor splice-site mutations in WT1 are responsible for Frasier syndrome. *Nat Genet* 1997;17:467–470.
30. Sergi C, Kos M. Bilateral Wilms' tumor in trisomy 18 syndrome: case report and critical review of the literature. *Ann Clin Lab Sci* 2018;48:369–372.
31. Oh L, Hafsi H, Hainaut P, et al. p53, stem cell biology and childhood blastomas. *Curr Opin Oncol* 2019;31:84–91.
32. Astuti D, Morris MR, Cooper WN, et al. Germline mutations in DIS3L2 cause the Perlman syndrome of overgrowth and Wilms tumor susceptibility. *Nat Genet* 2012;44:277–284.
33. Russell B, Tan WH, Graham Jr JM. Bohring-Opitz Syndrome. In: Adam MP, Ardinger HH, Pagon RA, eds. *GeneReviews*®. [Internet]. Seattle, WA: University of Washington, Seattle; 2018.
34. Hoischen A, van Bon BW, Rodríguez-Santiago B, et al. De novo nonsense mutations in ASXL1 cause Bohring-Opitz syndrome. *Nat Genet* 2011;43:729–731.
35. Hämäläinen RH, Mowat D, Gabbett MT, et al. Wilms' tumor and novel TRIM37 mutations in an Australian patient with mulibrey nanism. *Clin Genet* 2006;70:473–479.
36. Breslow NE, Beckwith JB. Epidemiological features of Wilms' tumor: results of the National Wilms' Tumor Study. *J Natl Cancer Inst* 1982;68:429–436.
37. Pendergrass TW. Congenital anomalies in children with Wilms' tumor: a new survey. *Cancer* 1976;37:403–408.
38. Palmer N, Evans AE. The association of aniridia and Wilms' tumor: methods of surveillance and diagnosis. *Med Pediatr Oncol* 1983;11:73–75.
39. Charlton J, Irtan S, Bergeron C, et al. Bilateral Wilms tumour: a review of clinical and molecular features. *Expert Rev Mol Med* 2017;19:e8.
40. Gadd S, Huff V, Huang CC, et al. Clinically relevant subsets identified by gene expression patterns support a revised ontogenic model of Wilms tumor: a Children's Oncology Group Study. *Neoplasia* 2012;14:742–756.
41. Gutjahr P. Progress and controversies in modern treatment of Wilms' tumors. *World J Urol* 1995;13:209–212.
42. Gessler M, Poustka A, Cavenee W, et al. Homozygous deletion in Wilms tumours of a zinc-finger gene identified by chromosome jumping. *Nature* 1990;343:774–778.
43. Bonetta L, Kuehn SE, Huang A, et al. Wilms tumor locus on 11p13 defined by multiple CpG island-associated transcripts. *Science* 1990;250:994–997.
44. Mahamdallie S, Yost S, Poyastro-Pearson E, et al. Identification of new Wilms tumour predisposition genes: an exome sequencing study. *Lancet Child Adolesc Health* 2019;3:322–331.
45. Mahamdallie SS, Hanks S, Karlin KL, et al. Mutations in the transcriptional repressor REST predispose to Wilms tumor. *Nat Genet* 2015;47:1471–1474.
46. Gadd S, Huff V, Walz AL, et al. A Children's Oncology Group and TARGET initiative exploring the genetic landscape of Wilms tumor. *Nat Genet* 2017;49:1487–1494.
47. McDonald JM, Douglass EC, Fisher R, et al. Linkage of familial Wilms' tumor predisposition to chromosome 19 and a two-locus model for the etiology of familial tumors. *Cancer Res* 1998;58:1387–1390.
48. Rahman N, Arbour L, Tonin P, et al. Evidence for a familial Wilms' tumour gene (FWT1) on chromosome 17q12-q21. *Nat Genet* 1996;13:461–463.
49. Grundy P, Koufos A, Morgan K, et al. Familial predisposition to Wilms' tumour does not map to the short arm of chromosome 11. *Nature* 1988;336:374–376.
50. Srinivasan AS, Saade-Lemus S, Servaes SE, et al. Imaging surveillance for children with predisposition to renal tumors. *Pediatr Radiol* 2019;49:1453–1462.
51. Brioude F, Kalish JM, Mussa A, et al. Expert consensus document: clinical and molecular diagnosis, screening and management of Beckwith-Wiedemann syndrome: an international consensus statement. *Nat Rev Endocrinol* 2018;14:229–249.
52. Liu EK, Suson KD. Syndromic Wilms tumor: a review of predisposing conditions, surveillance and treatment. *Transl Androl Urol* 2020;9:2370–2381.
53. Scott RH, Walker L, Olsen ØE, et al. Surveillance for Wilms tumour in at-risk children: pragmatic recommendations for best practice. *Arch Dis Child* 2006;91:995–999.
54. Chung EM, Graeber AR, Conran RM. Renal tumors of childhood: radiologic-pathologic correlation part 1. The 1st decade: from the Radiologic Pathology Archives. *Radiographics* 2016;36:499–522.
55. McDonald K, Duffy P, Chowdhury T, et al. Added value of abdominal cross-sectional imaging (CT or MRI) in staging of Wilms' tumours. *Clin Radiol* 2013;68:16–20.
56. Servaes S, Khanna G, Naranjo A, et al. Comparison of diagnostic performance of CT and MRI for abdominal staging of pediatric renal tumors: a report from the Children's Oncology Group. *Pediatr Radiol* 2015;45:166–172.
57. Brisse HJ, Smets AM, Kaste SC, et al. Imaging in unilateral Wilms tumour. *Pediatr Radiol* 2008;38:18–29.
58. Hamilton TE, Green DM, Perlman EJ, et al. Bilateral Wilms' tumor with anaplasia: lessons from the National Wilms' Tumor Study. *J Pediatr Surg* 2006;41:1641–1644.
59. Beckwith JB. Nephrogenic rests and the pathogenesis of Wilms tumor: developmental and clinical considerations. *Am J Med Genet* 1998;79:268–273.
60. Dome JS, Coppes MJ. Recent advances in Wilms tumor genetics. *Curr Opin Pediatr* 2002;14:5–11.
61. Ehrlich P, Chi YY, Chintagumpala MM, et al. Results of the first prospective multi-institutional treatment study in children with bilateral Wilms tumor (AREN0534): a report From the Children's Oncology Group. *Ann Surg* 2017;266:470–478.
62. Gow KW, Roberts IF, Jamieson DH, et al. Local staging of Wilms' tumor—computerized tomography correlation with histological findings. *J Pediatr Surg* 2000;35:677–679.
63. Qureshi SS, Bhagat M, Kazi M, et al. Standardizing lymph nodal sampling for Wilms tumor: a feasibility study with outcomes. *J Pediatr Surg* 2020;55:2668–2675.
64. Nelson MV, van den Heuvel-Eibrink MM, Graf N, et al. New approaches to risk stratification for Wilms tumor. *Curr Opin Pediatr* 2021;33:40–48.

65. Termuhlen AM, Tersak JM, Liu Q, et al. Twenty-five year follow-up of childhood Wilms tumor: a report from the Childhood Cancer Survivor Study. *Pediatr Blood Cancer* 2011;57:1210-1216.
66. Lange JM, Takashima JR, Peterson SM, et al. Breast cancer in female survivors of Wilms tumor: a report from the national Wilms tumor late effects study. *Cancer* 2014;120:3722-3730.
67. Breslow NE, Takashima JR, Whitton JA, et al. Second malignant neoplasms following treatment for Wilms' tumor: a report from the National Wilms' Tumor Study Group. *J Clin Oncol* 1995;13:1851-1859.
68. Paulino AC, Wen BC, Brown CK, et al. Late effects in children treated with radiation therapy for Wilms' tumor. *Int J Radiat Oncol Biol Phys* 2000;46:1239-1246.
69. Lemerle J, Voute PA, Tournade MF, et al. Effectiveness of preoperative chemotherapy in Wilms' tumor: results of an International Society of Paediatric Oncology (SIOP) clinical trial. *J Clin Oncol* 1983;1:604-609.
70. Tournade MF, Com-Nougé C, de Kraker J, et al. Optimal duration of preoperative therapy in unilateral and nonmetastatic Wilms' tumor in children older than 6 months: results of the Ninth International Society of Pediatric Oncology Wilms' Tumor Trial and Study. *J Clin Oncol* 2001;19:488-500.
71. Gow KW, Barnhart DC, Hamilton TE, et al. Primary nephrectomy and intraoperative tumor spill: report from the Children's Oncology Group (COG) renal tumors committee. *J Pediatr Surg* 2013;48:34-38.
72. Zhuge Y, Cheung MC, Yang R, et al. Improved survival with lymph node sampling in Wilms tumor. *J Surg Res* 2011;167:e199-e203.
73. Ehrlich PF, Anderson JR, Ritchey ML, et al. Clinicopathologic findings predictive of relapse in children with stage III favorable-histology Wilms tumor. *J Clin Oncol* 2013;31:1196-1201.
74. Breslow N, Sharples K, Beckwith JB, et al. Prognostic factors in nonmetastatic, favorable histology Wilms' tumor. Results of the Third National Wilms' Tumor Study. *Cancer* 1991;68:2345-2353.
75. Fernandez CV, Mullen EA, Chi YY, et al. Outcome and prognostic factors in stage III favorable-histology Wilms tumor: a report from the Children's Oncology Group Study AREN0532. *J Clin Oncol* 2018;36:254-261.
76. D'Angio GJ, Evans A, Breslow N, et al. The treatment of Wilms' tumor: results of the Second National Wilms' Tumor Study. *Cancer* 1981;47:2302-2311.
77. Ritchey ML, Shamberger RC, Haase G, et al. Surgical complications after primary nephrectomy for Wilms' tumor: report from the National Wilms' Tumor Study Group. *J Am Coll Surg* 2001;192:63-68., quiz 146.
78. Ritchey ML, Kelalis PP, Breslow N, et al. Surgical complications after nephrectomy for Wilms' tumor. *Surg Gynecol Obstet* 1992;175:507-514.
79. Davidoff AM, Giel DW, Jones DP, et al. The feasibility and outcome of nephron-sparing surgery for children with bilateral Wilms tumor. The St Jude Children's Research Hospital experience: 1999-2006. *Cancer* 2008;112:2060-2070.
80. Khanna G, Rosen N, Anderson JR, et al. Evaluation of diagnostic performance of CT for detection of tumor thrombus in children with Wilms tumor: a report from the Children's Oncology Group. *Pediatr Blood Cancer* 2012;58:551-555.
81. Kalapurakal JA, Li SM, Breslow NE, et al. Intraoperative spillage of favorable histology Wilms tumor cells: influence of irradiation and chemotherapy regimens on abdominal recurrence. A report from the National Wilms Tumor Study Group. *Int J Radiat Oncol Biol Phys* 2010;76:201-206.
82. D'Angio GJ. SIOP (International Society of Paediatric Oncology) and the management of Wilms' tumor. *J Clin Oncol* 1983;1:595-596.
83. D'Angio GJ, Evans AE, Breslow N, et al. The treatment of Wilms' tumor: results of the national Wilms' tumor study. *Cancer* 1976;38:633-646.
84. Kieran K, Ehrlich PF. Current surgical standards of care in Wilms tumor. *Urol Oncol* 2016;34:13-23.
85. Aldrink JH, Heaton TE, Dasgupta R, et al. Update on Wilms tumor. *J Pediatr Surg* 2019;54:390-397.
86. Kieran K, Anderson JR, Dome JS, et al. Is adrenalectomy necessary during unilateral nephrectomy for Wilms Tumor? A report from the Children's Oncology Group. *J Pediatr Surg* 2013;48:1598-1603.
87. Shamberger RC, Guthrie KA, Ritchey ML, et al. Surgery-related factors and local recurrence of Wilms tumor in National Wilms Tumor Study 4. *Ann Surg* 1999;229:292-297.
88. Wong KF, Reulen RC, Winter DL, et al. Risk of adverse health and social outcomes up to 50 years after Wilms tumor: the British Childhood Cancer Survivor Study. *J Clin Oncol* 2016;34:1772-1779.
89. Cone EB, Dalton SS, Van Noord M, et al. Biomarkers for Wilms tumor: a systematic review. *J Urol* 2016;196:1530-1535.
90. Grundy PE, Breslow NE, Li S, et al. Loss of heterozygosity for chromosomes 1p and 16q is an adverse prognostic factor in favorable-histology Wilms tumor: a report from the National Wilms Tumor Study Group. *J Clin Oncol* 2005;23:7312-7321.
91. Green DM, Breslow NE, Beckwith JB, et al. Effect of duration of treatment on treatment outcome and cost of treatment for Wilms' tumor: a report from the National Wilms' Tumor Study Group. *J Clin Oncol* 1998;16:3744-3751.
92. Dix DB, Seibel NL, Chi YY, et al. Treatment of stage IV favorable histology Wilms tumor with lung metastases: a report from the Children's Oncology Group AREN0533 Study. *J Clin Oncol* 2018;36:1564-1570.
93. Green DM, Breslow NE, Beckwith JB, et al. Comparison between single-dose and divided-dose administration of dactinomycin and doxorubicin for patients with Wilms' tumor: a report from the National Wilms' Tumor Study Group. *J Clin Oncol* 1998;16:237-245.
94. Seibel NL, Chi YY, Perlman EJ, et al. Impact of cyclophosphamide and etoposide on outcome of clear cell sarcoma of the kidney treated on the National Wilms Tumor Study-5 (NWTS-5). *Pediatr Blood Cancer* 2019;66:e27450.
95. Shamberger RC, Haase GM, Argani P, et al. Bilateral Wilms' tumors with progressive or nonresponsive disease. *J Pediatr Surg* 2006;41:652-657. discussion 652-657.
96. Hua CH, Vern-Gross TZ, Hess CB, et al. Practice patterns and recommendations for pediatric image-guided radiotherapy: a Children's Oncology Group report. *Pediatr Blood Cancer* 2020;67:e28629.
97. Jereb B, Burgers JM, Tournade MF, et al. Radiotherapy in the SIOP (International Society of Pediatric Oncology) nephroblastoma studies: a review. *Med Pediatr Oncol* 1994;22:221-227.
98. Kalapurakal JA, Gopalakrishnan M, Walterhouse DO, et al. Cardiac-sparing whole lung IMRT in patients with pediatric tumors and lung metastasis: final report of a prospective multicenter clinical trial. *Int J Radiat Oncol Biol Phys* 2019;103:28-37.
99. Kalapurakal JA, Lee B, Bautista J, et al. Cardiac-sparing whole lung intensity modulated radiation therapy in children with Wilms tumor: final report on technique and abdominal field matching to maximize normal tissue protection. *Pract Radiat Oncol* 2019;9:e62-73.
100. Kalapurakal JA, Zhang Y, Kepka A, et al. Cardiac-sparing whole lung IMRT in children with lung metastasis. *Int J Radiat Oncol Biol Phys* 2013;85:761-767.
101. Stokes CL, Stokes WA, Kalapurakal JA, et al. Timing of radiation therapy in pediatric Wilms tumor: a report from the National Cancer Database. *Int J Radiat Oncol Biol Phys* 2018;101:453-461.
102. Kalapurakal JA, Li SM, Breslow NE, et al. Influence of radiation therapy delay on abdominal tumor recurrence in patients with favorable histology Wilms' tumor treated on NWTS-3 and NWTS-4: a report from the National Wilms' Tumor Study Group. *Int J Radiat Oncol Biol Phys* 2003;57:495-499.
103. D'Angio GJ, Tefft M, Breslow N, et al. Radiation therapy of Wilms' tumor: results according to dose, field, post-operative timing and histology. *Int J Radiat Oncol Biol Phys* 1978;4:769-780.
104. Hudson MM, Mertens AC, Yasui Y, et al. Health status of adult long-term survivors of childhood cancer: a report from the Childhood Cancer Survivor Study. *JAMA* 2003;290:1583-1592.
105. Dix DB, Fernandez CV, Chi YY, et al. Augmentation of therapy for combined loss of heterozygosity 1p and 16q in favorable histology Wilms tumor: a Children's Oncology Group AREN0532 and AREN0533 Study Report. *J Clin Oncol* 2019;37:2769-2777.
106. Malogolowkin M, Cotton CA, Green DM, et al. Treatment of Wilms tumor relapsing after initial treatment with vincristine, actinomycin D, and doxorubicin: a report from the National Wilms Tumor Study Group. *Pediatr Blood Cancer* 2008;50:236-241.
107. Green DM, Cotton CA, Malogolowkin M, et al. Treatment of Wilms tumor relapsing after initial treatment with vincristine and actinomycin D: a report from the National Wilms Tumor Study Group. *Pediatr Blood Cancer* 2007;48:493-499.
108. Practice Committee of the American Society for Reproductive Medicine. Electronic address: asrm@asrm.org. Fertility preservation in patients undergoing gonadotoxic therapy or gonadectomy: a committee opinion. *Fertil Steril* 2019;112:1022-1033.
109. Lee SJ, Schover LR, Partridge AH, et al. American Society of Clinical Oncology recommendations on fertility preservation in cancer patients. *J Clin Oncol* 2006;24:2917-2931.
110. Brok J, Lopez-Yurda M, Tinteren HV, et al. Relapse of Wilms' tumour and detection methods: a retrospective analysis of the 2001 Renal Tumour Study Group-International Society of Paediatric Oncology Wilms' tumour protocol database. *Lancet Oncol* 2018;19:1072-1081.

111. Mullen EA, Chi YY, Hibbitts E, et al. Impact of surveillance imaging modality on survival after recurrence in patients with favorable-histology Wilms tumor: a report from the Children's Oncology Group. *J Clin Oncol* 2018;36:JCO1800076.
112. Fernandez CV, Perlman EJ, Mullen EA, et al. Clinical outcome and biological predictors of relapse after nephrectomy only for very low-risk Wilms tumor: a report from Children's Oncology Group AREN0532. *Ann Surg* 2017;265:835–840.
113. Shamberger RC, Anderson JR, Breslow NE, et al. Long-term outcomes for infants with very low risk Wilms tumor treated with surgery alone in National Wilms Tumor Study-5. *Ann Surg* 2010;251:555–558.
114. Ehrlich PF, Chi YY, Chintagumpala MM, et al. Results of treatment for patients with multicentric or bilaterally predisposed unilateral Wilms tumor (AREN0534): a report from the Children's Oncology Group. *Cancer* 2020;126:3516–3525.
115. Farber S, D'Angio G, Evans A, et al. Clinical studies on actinomycin D with special reference to Wilms' tumor in children. *Ann N Y Acad Sci* 1960;89:421–425.
116. Green DM, Breslow NE, Beckwith JB, et al. Treatment outcomes in patients less than 2 years of age with small, stage I, favorable-histology Wilms' tumors: a report from the National Wilms' Tumor Study. *J Clin Oncol* 1993;11:91–95.
117. Green DM. Augmentation of therapy for combined loss of heterozygosity 1p and 16q in favorable histology Wilms tumor. *J Clin Oncol* 2020;38:772–773.
118. Green DM. Treatment of stage IV favorable histology Wilms tumor with lung metastases. *J Clin Oncol* 2018;36:JCO1800101.
119. Gratijs EJ, Jennings LJ, Anderson JR, et al. Gain of 1q is associated with inferior event-free and overall survival in patients with favorable histology Wilms tumor: a report from the Children's Oncology Group. *Cancer* 2013;119:3887–3894.
120. Le Deley MC, Leblanc T, Shamsaldin A, et al. Risk of secondary leukemia after a solid tumor in childhood according to the dose of epipodophylotoxins and anthracyclines: a case-control study by the Société Française d'Oncologie Pédiatrique. *J Clin Oncol* 2003;21:1074–1081.
121. Green DM, Liu W, Kutteh WH, et al. Cumulative alkylating agent exposure and semen parameters in adult survivors of childhood cancer: a report from the St Jude Lifetime Cohort Study. *Lancet Oncol* 2014;15:1215–1223.
122. Vujanić GM, Sandstedt B, Harms D, et al. Revised International Society of Paediatric Oncology (SIOP) working classification of renal tumors of childhood. *Med Pediatr Oncol* 2002;38:79–82.
123. Porteus MH, Narkool P, Neuberger D, et al. Characteristics and outcome of children with Beckwith-Wiedemann syndrome and Wilms' tumor: a report from the National Wilms Tumor Study Group. *J Clin Oncol* 2000;18:2026–2031.
124. Hamilton TE, Ritchey ML, Haase GM, et al. The management of synchronous bilateral Wilms tumor: a report from the National Wilms Tumor Study Group. *Ann Surg* 2011;253:1004–1010.
125. Davidoff AM, Interiano RB, Wynn L, et al. Overall survival and renal function of patients with synchronous bilateral Wilms tumor undergoing surgery at a single institution. *Ann Surg* 2015;262:570–576.



Individual Disclosures for the NCCN Wilms Tumor (Nephroblastoma) Panel				
Panel Member	Clinical Research Support/ Data Safety Monitoring Board	Scientific Advisory Boards, Consultant, or Expert Witness	Promotional Advisory Boards, Consultant, or Speakers Bureau	Specialties
Clarke Anderson, MD	None	None	None	Pediatric Oncology, and Hematology/Hematology Oncology
Frank Balis, MD	Amgen Inc.; Bayer HealthCare; Daiichi- Sankyo Co.; Eisai Inc.; Eli Lilly and Company; Novartis Pharmaceuticals Corporation; Pfizer Inc.; and Roche Laboratories, Inc.	None	None	Pediatric Oncology, and Pharmacology
Shelly Cook, MD	None	None	None	Pathology
Jasreman Dhillon, MD	None	None	None	Pathology
Kenneth Gow, MD, MHA	None	None	None	Pediatric Oncology, Surgery/Surgical Oncology
Daniel M. Green, MD	None	None	None	Pediatric Oncology
Susan Hiniker, MD	None	None	None	Radiotherapy/Radiation Oncology
Rama Jasty-Rao, MD	None	None	None	Pediatric Oncology
Chi Lin, MD, PhD	BioMimelix JV, LLC	None	None	Radiotherapy/Radiation Oncology
Harold Lovvorn III, MD	None	None	None	Surgery/Surgical Oncology
Iain MacEwan, MD	None	None	None	Radiotherapy/Radiation Oncology
Julian Martinez-Agosto, MD, PhD	None	None	None	Pediatric Oncology
Elizabeth Mullen, MD	None	None	None	Pediatric Oncology
Erin S. Murphy, MD	None	None	None	Radiotherapy/Radiation Oncology
Mark Ranalli, MD	None	None	None	Pediatric Oncology
Daniel Rhee, MD, MPH	None	None	None	Pediatric Oncology, and Surgery/ Surgical Oncology
Denise Rokitka, MD, MPH	None	None	None	Pediatric Oncology
Elisabeth (Lisa) Tracy, MD	None	None	None	Surgery/Surgical Oncology
Tamara Vern-Gross, DO	None	None	None	Radiotherapy/Radiation Oncology
Michael F. Walsh, MD	None	None	None	Pediatric Oncology, and Hematology/Hematology Oncology
Amy Walz, MD	None	None	None	Pediatric Oncology
Jonathan Wickiser, MD	None	None	None	Pediatric Oncology, and Hematology/Hematology Oncology
Matthew Zapala, MD, PhD	None	None	None	Radiotherapy/Radiation Oncology

The NCCN Guidelines Staff have no conflicts to disclose.