

Atrial Septal Defects Interesting Cases



Dawn Park, BS RDCS RCCS RDMS FASE
Pediatric and Fetal Cardiac Sonographer
Cardiac Educator
Nationwide Children's Hospital
Columbus Ohio



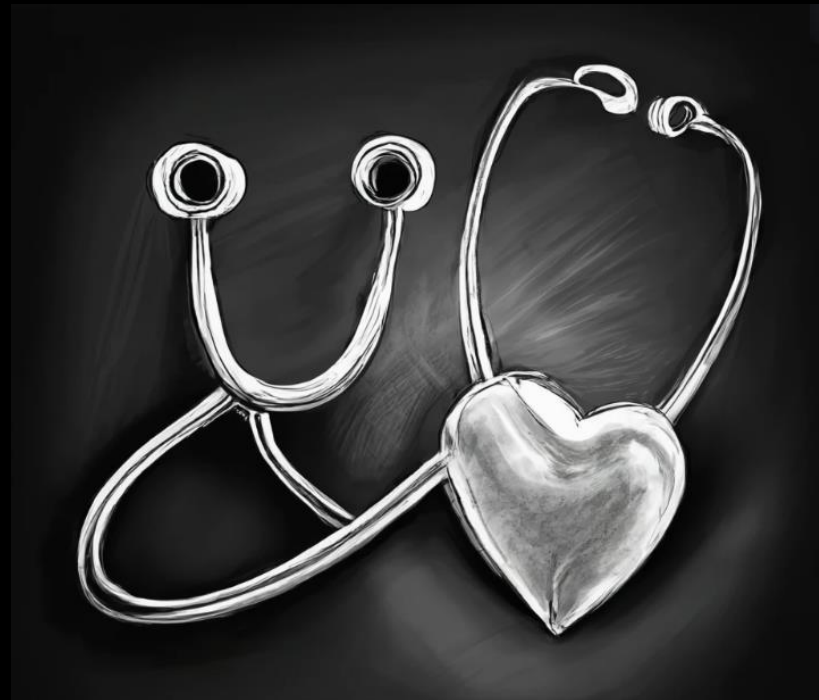NATIONWIDE CHILDREN'S
When your child needs a hospital, everything matters.



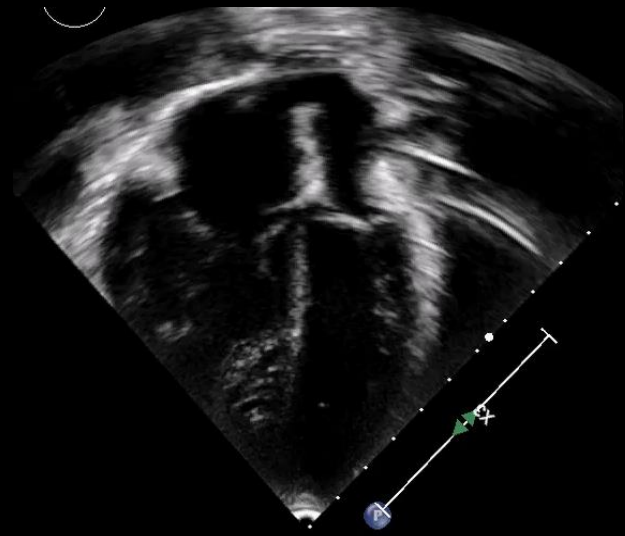
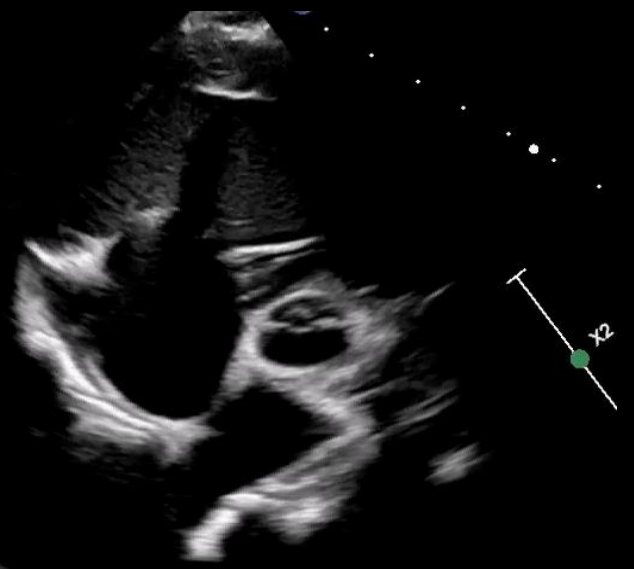
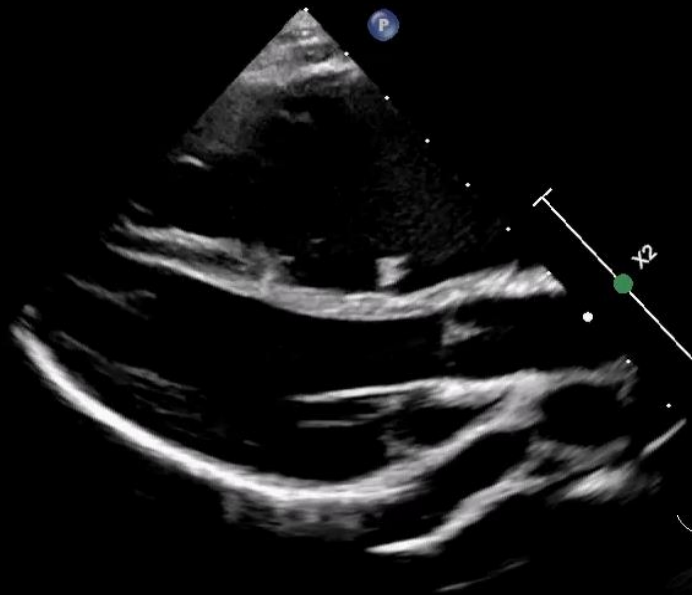
- No Disclosures

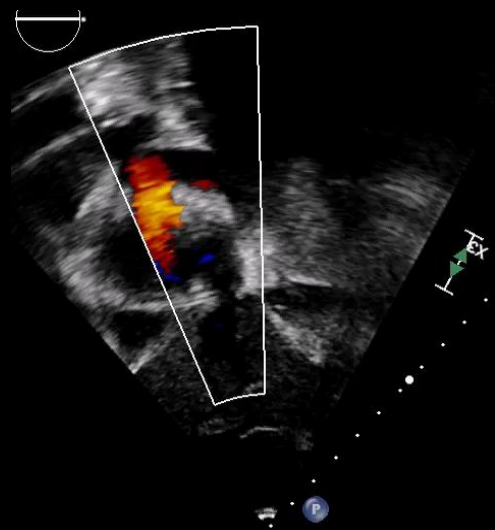
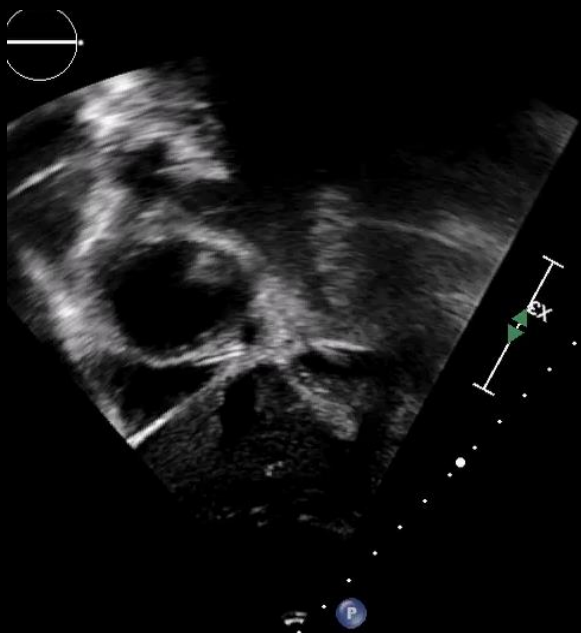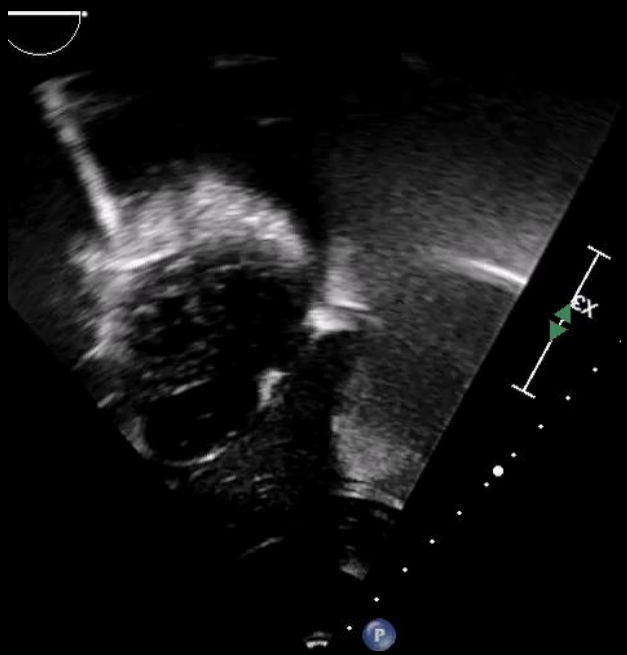7 Year old female

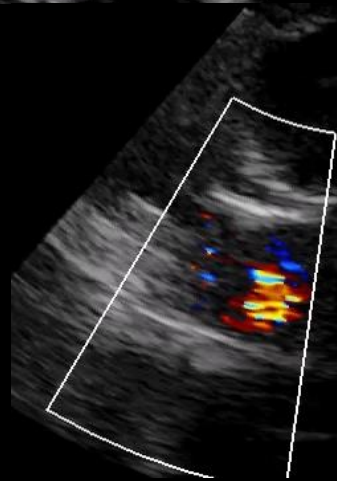
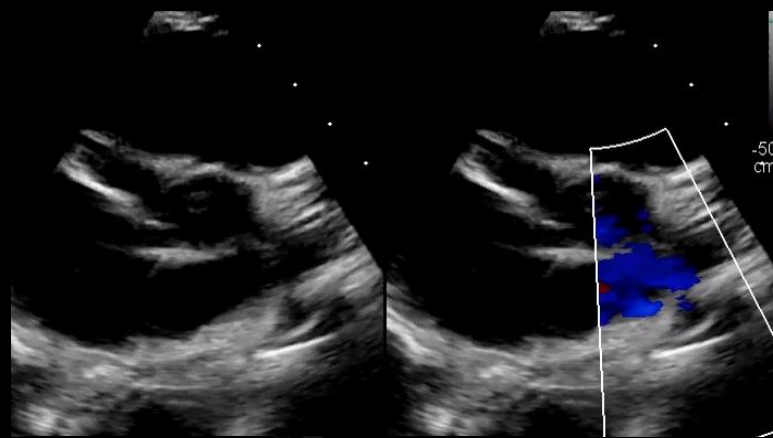
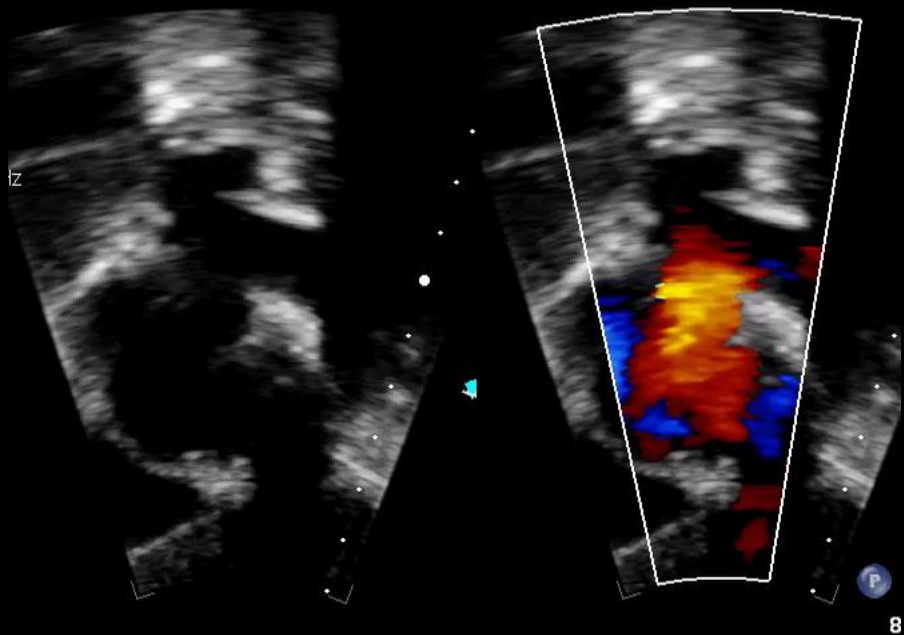
Murmur, well child check

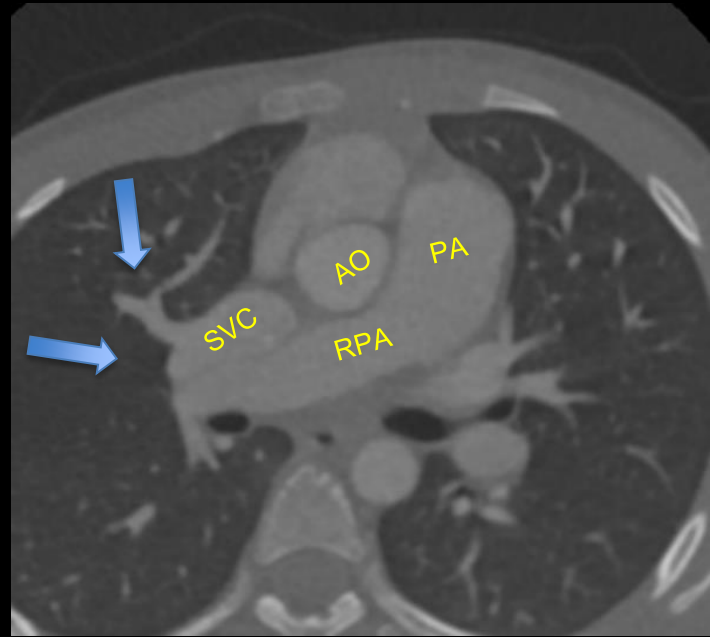
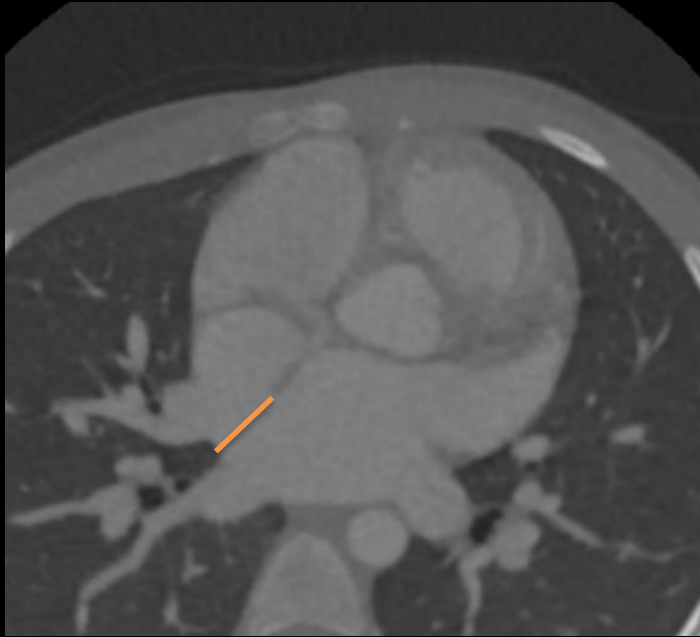


Off to echo.....

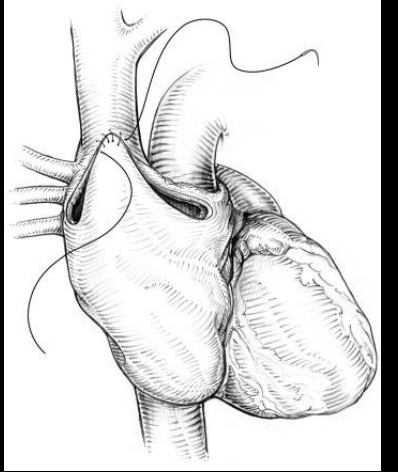
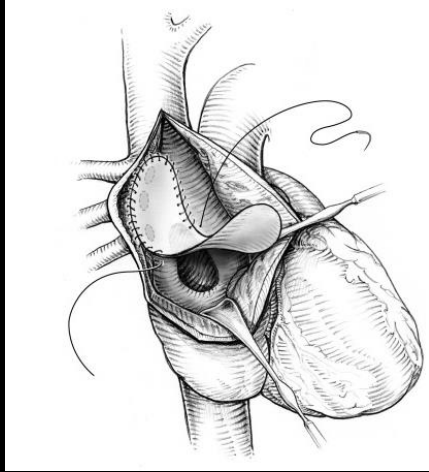
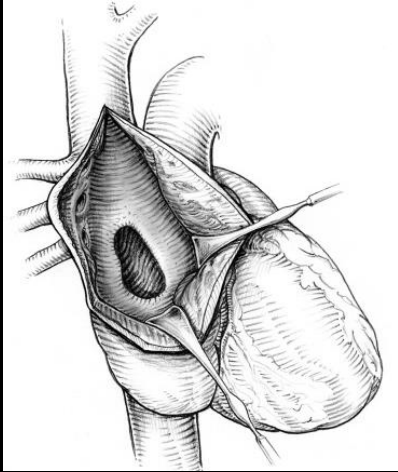
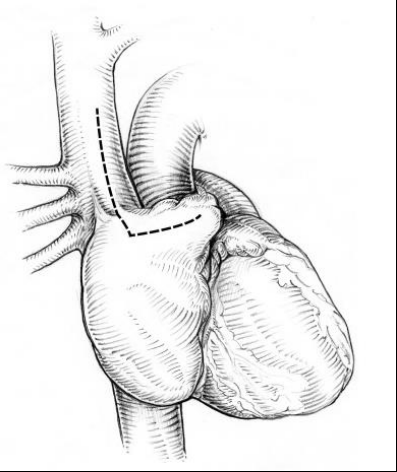


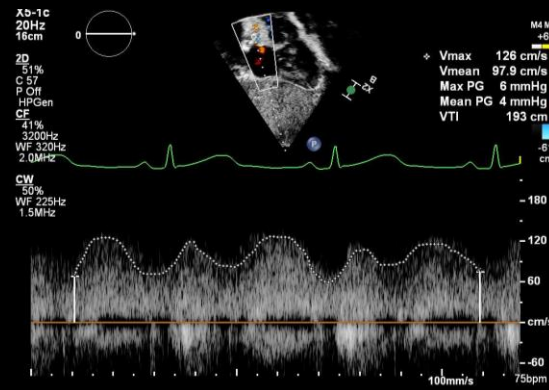
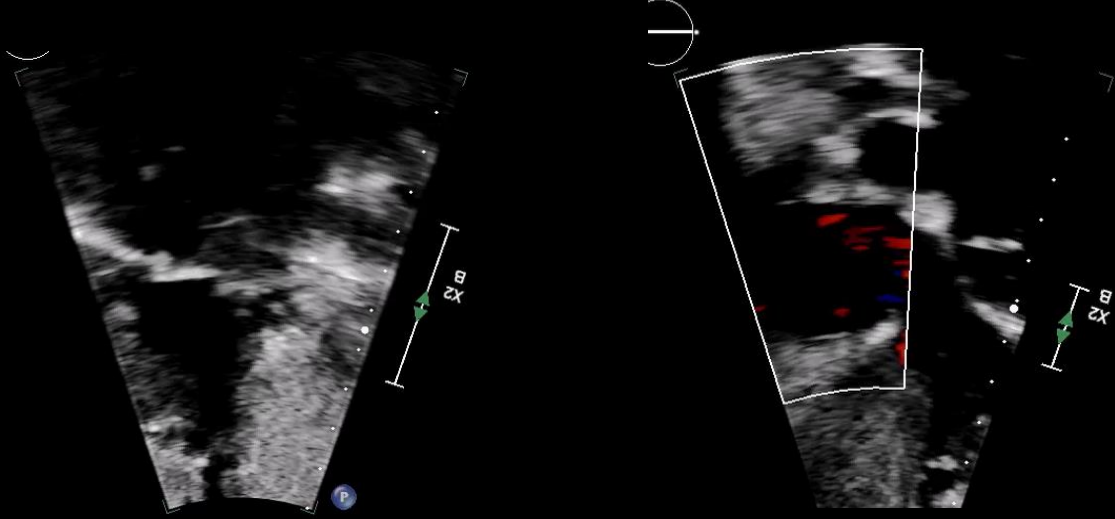
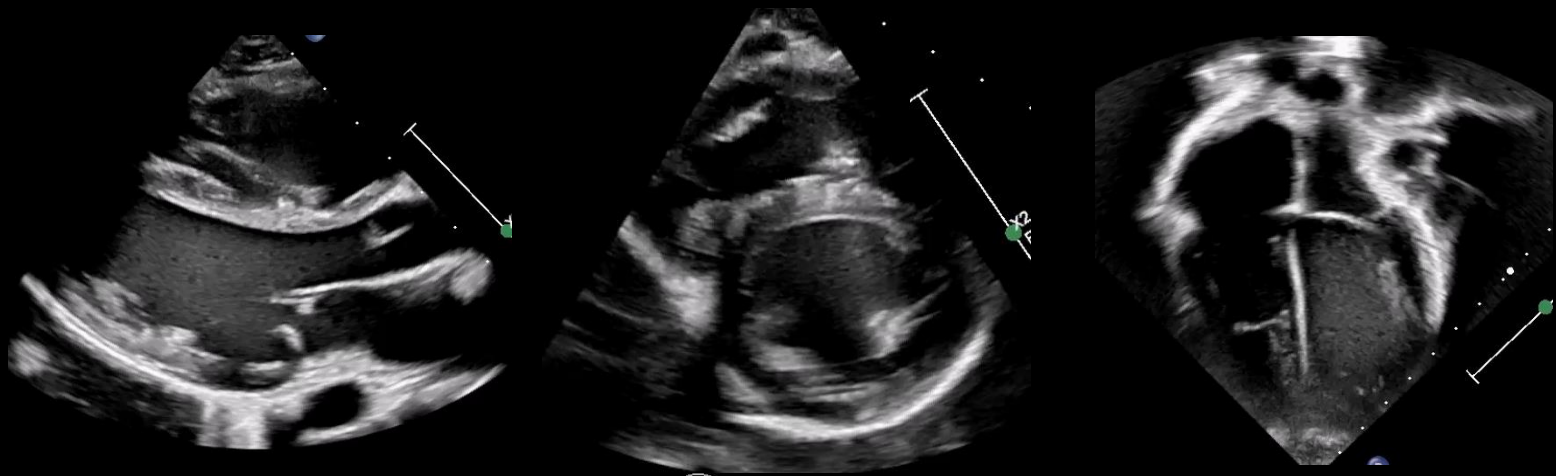


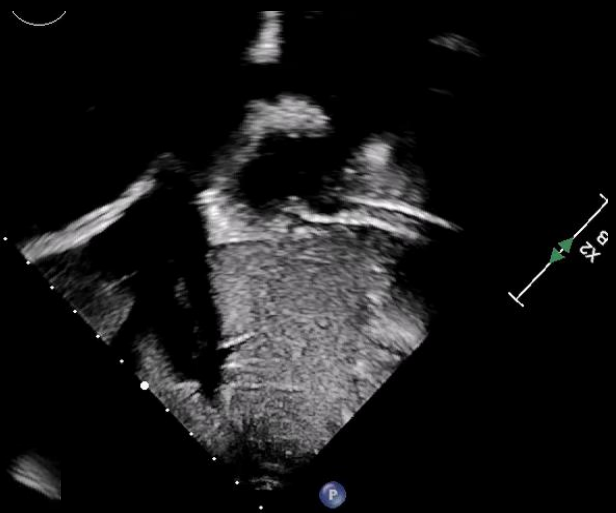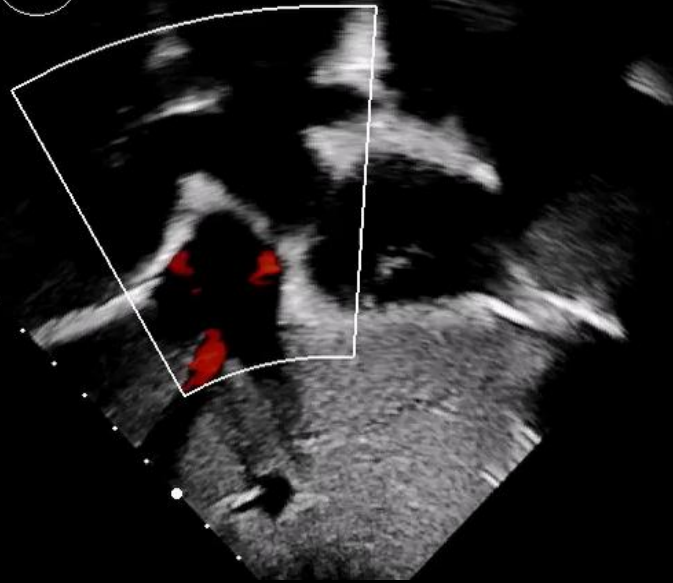

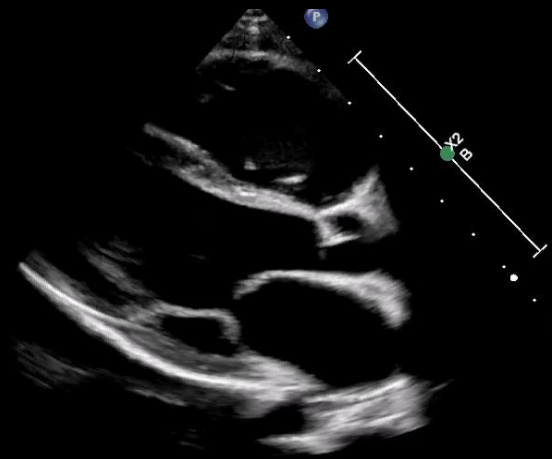
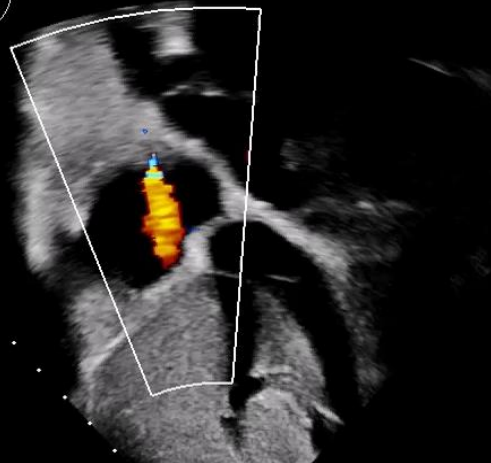
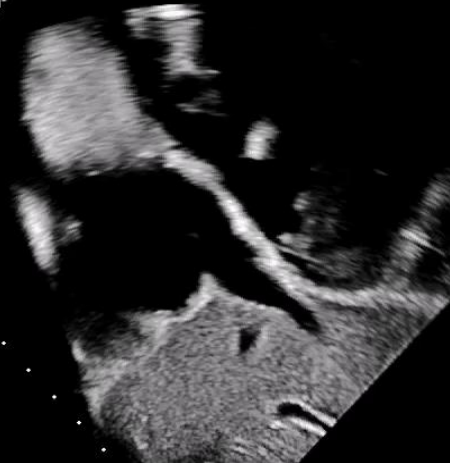


[Redacted text]









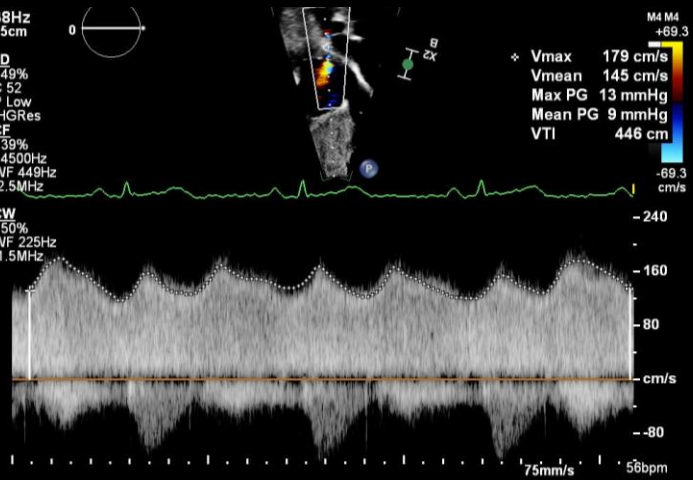
38Hz
15cm



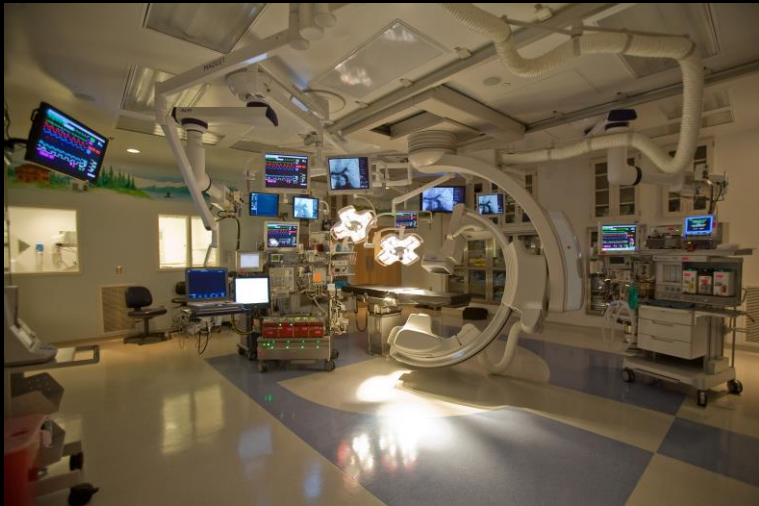2D
49%
C 52
P Low
HGRes

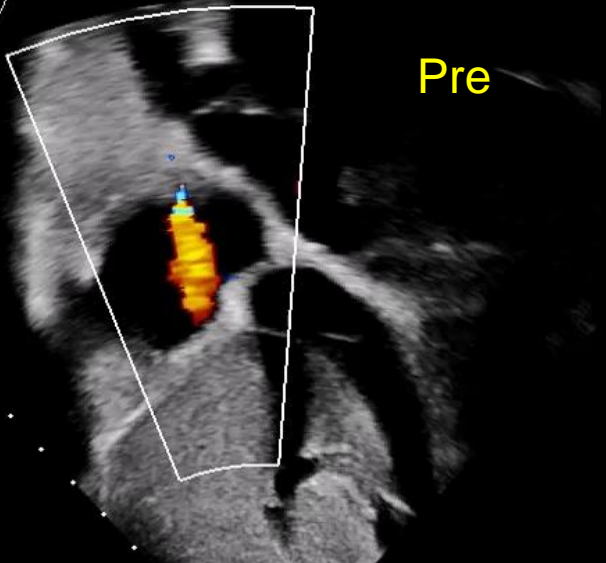
CF
39%
4.500Hz
WF 449Hz
2.5MHz

CW
50%
WF 225Hz
1.5MHz

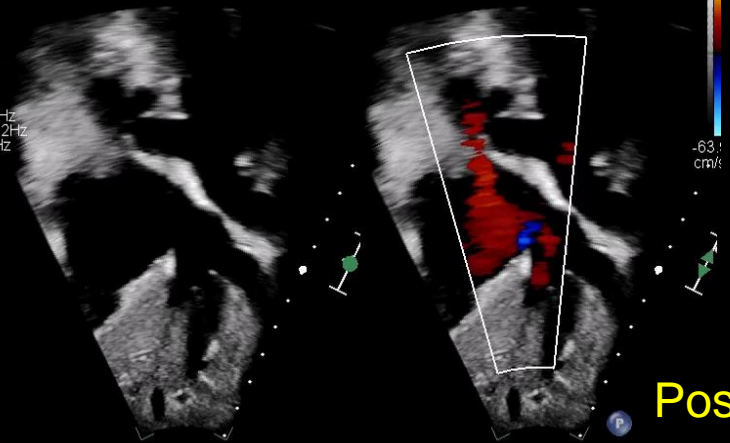


M4 M4
+69.3
Vmax 179 cm/s
Vmean 145 cm/s
Max PG 13 mmHg
Mean PG 9 mmHg
VTI 446 cm
-69.3
cm/s

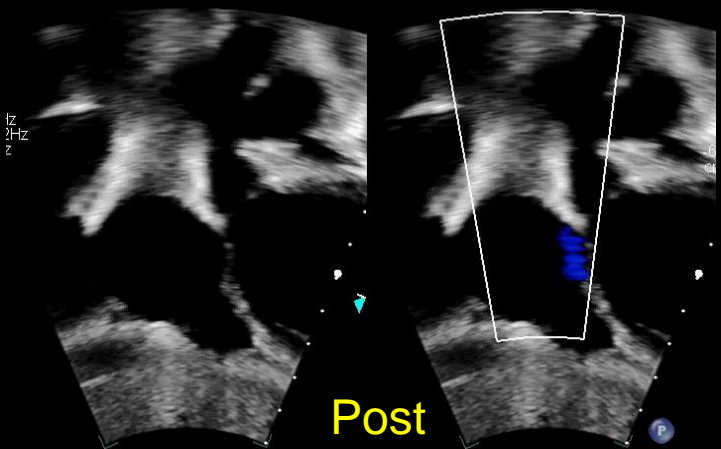




X5-1c
20Hz
17cm
2D
41%
C 57
P Off
HGen
CF
41%
3320Hz
WF 332Hz
2.0MHz



M
+63.1
-63.1
cm/s

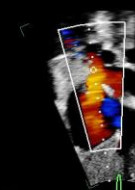


59 bpm

X5-1c
20Hz
17cm
2D
42%
C 57
P Off
HGen
CF
41%
2800Hz
WF 280Hz
2.0MHz



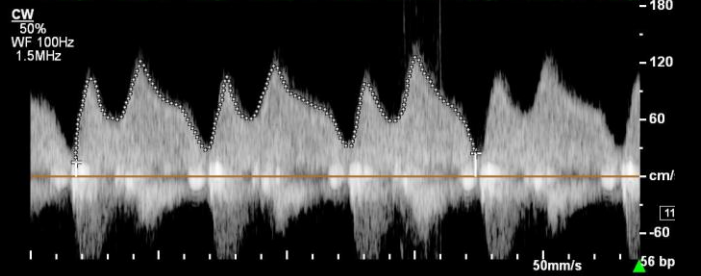
SVC



Vmax 125 cm/s
Vmean 76.3 cm/s
Max PG 6 mmHg
Mean PG 3 mmHg
VTI 238 cm

57 bpm

M4 A
+5
-5
cm

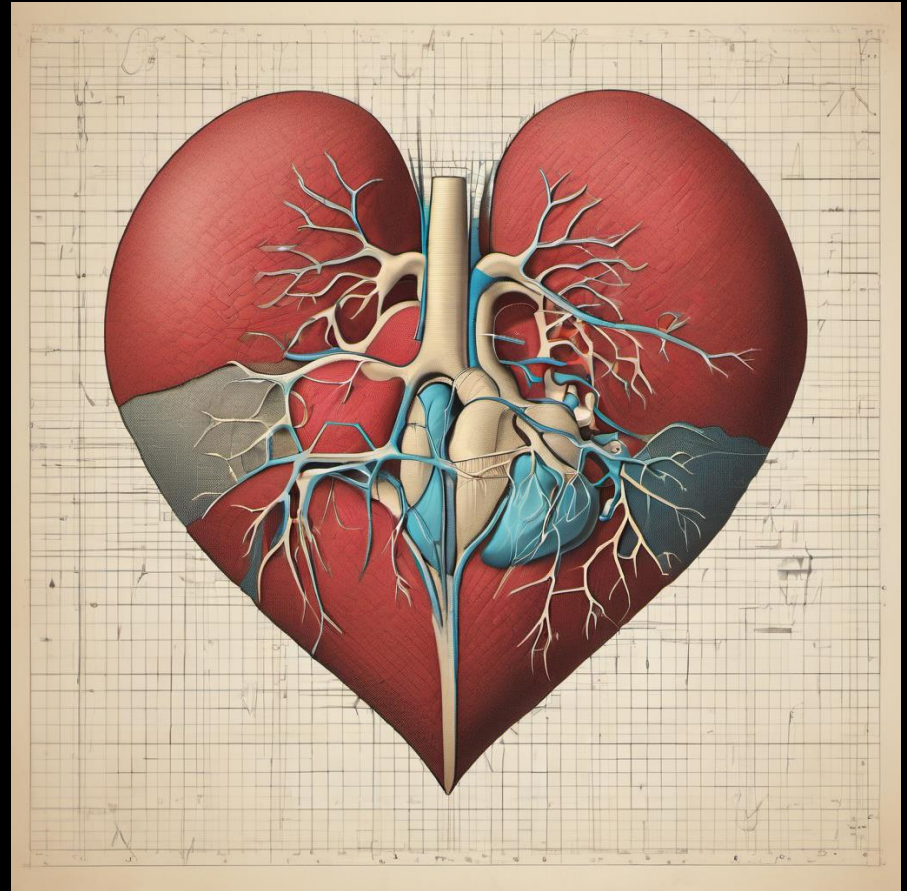


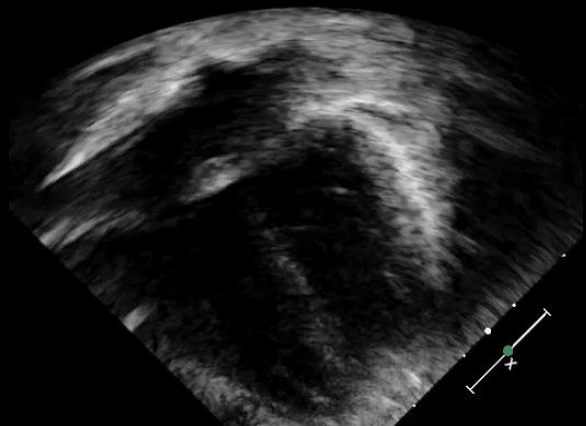
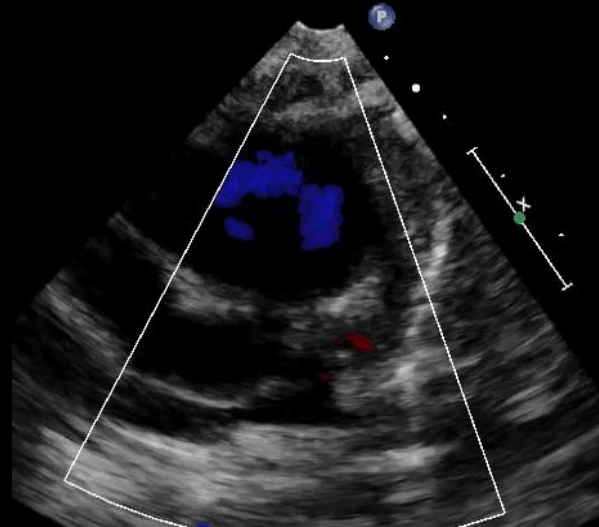
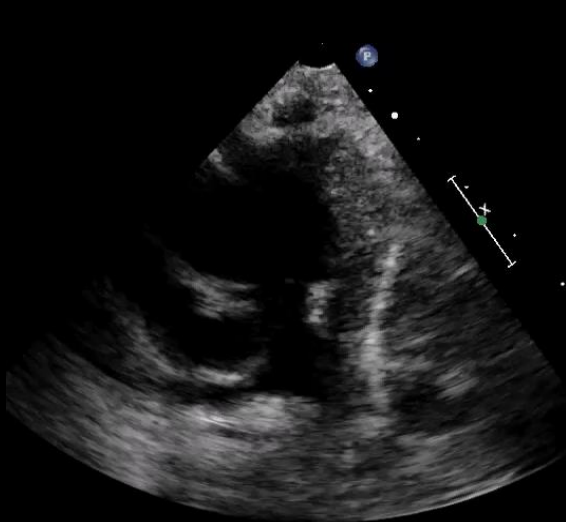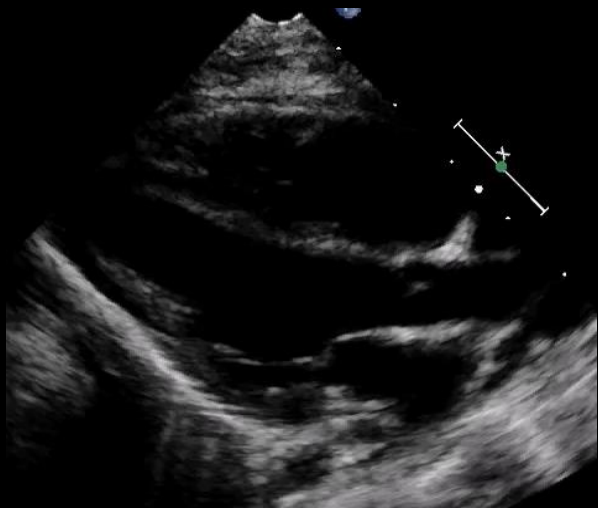
6 week old male

Abnormal ekg

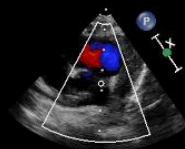Murmur

R/O Pulmonary Stenosis

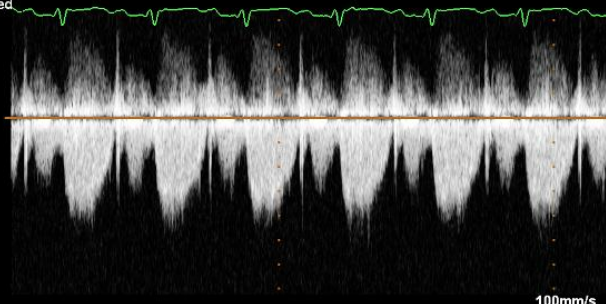





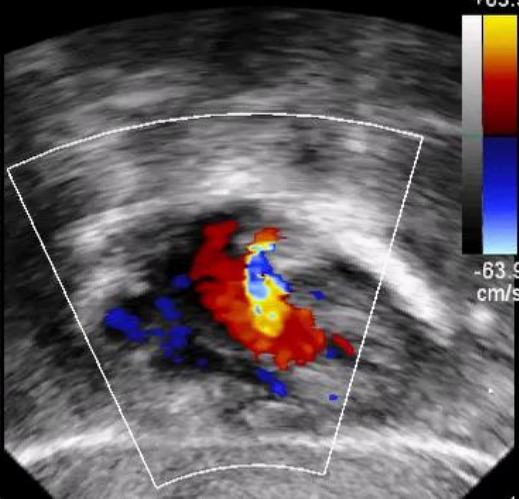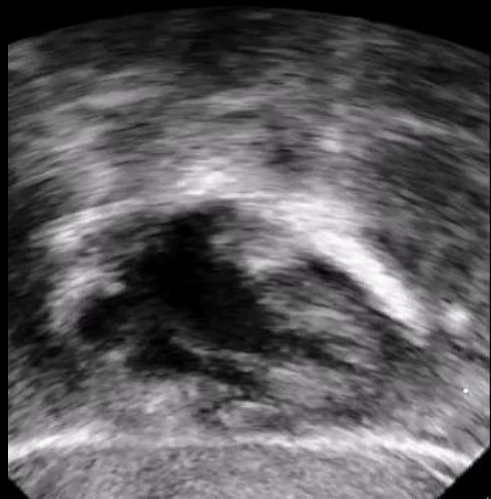
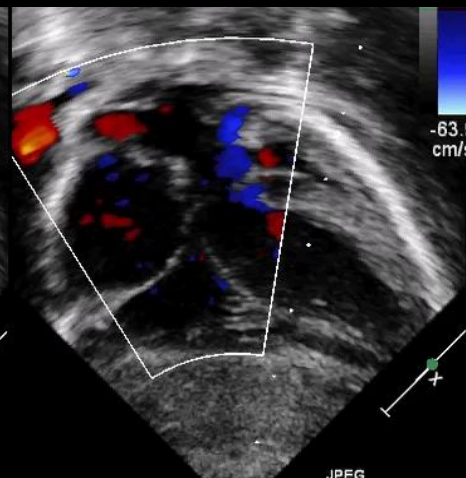
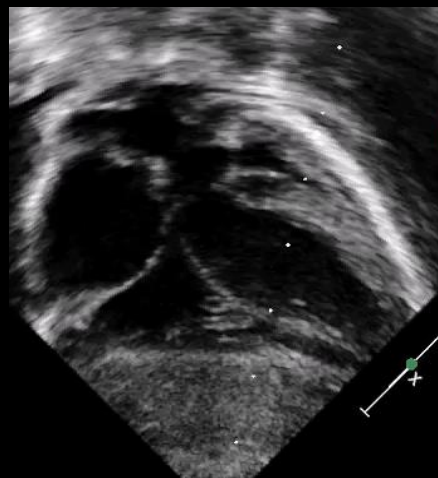
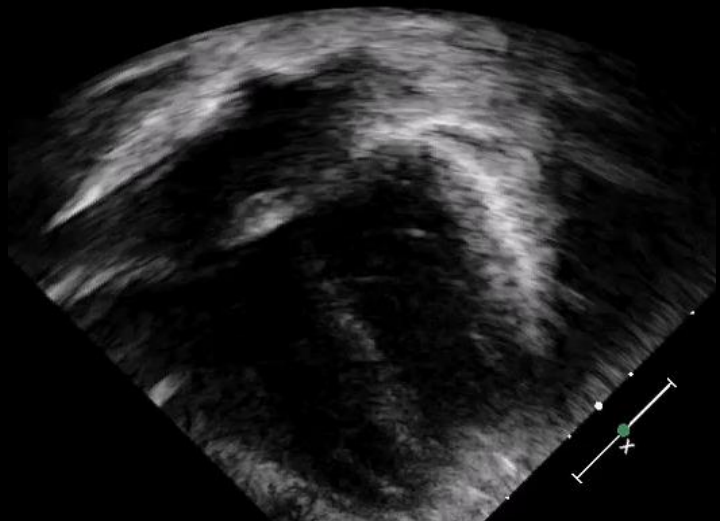
2D
68%
C 50
P Low
HGen
CF
77%
3.0MHz
WF High
Med



40%
3.3MHz
WF 225Hz



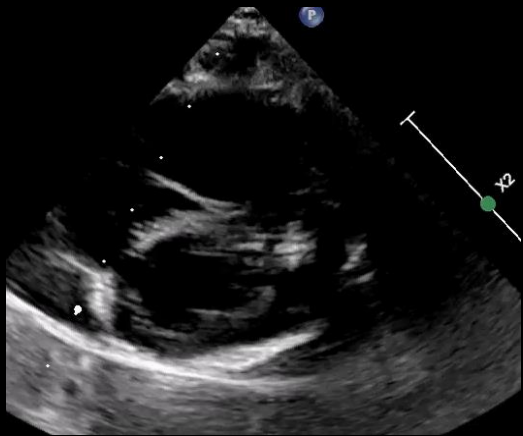
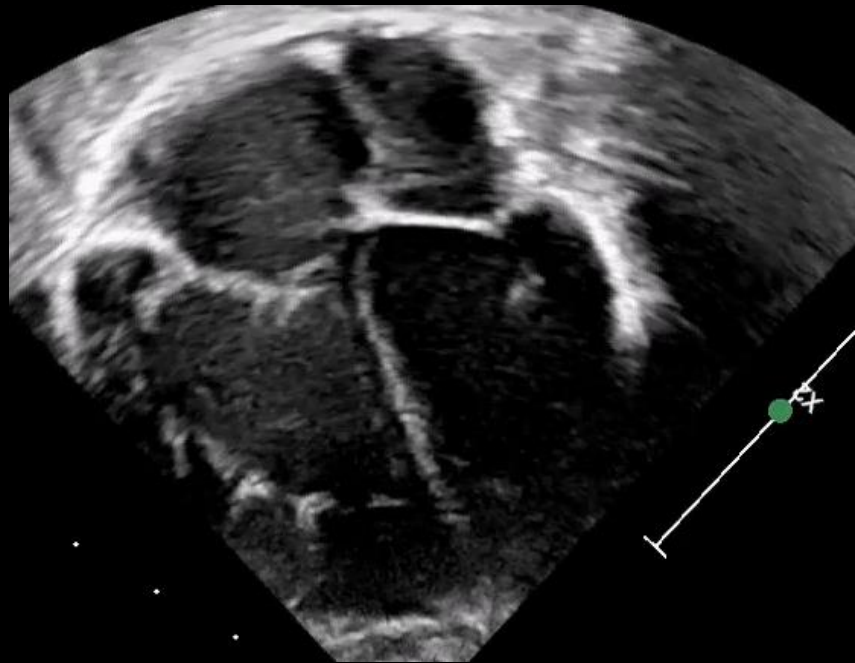
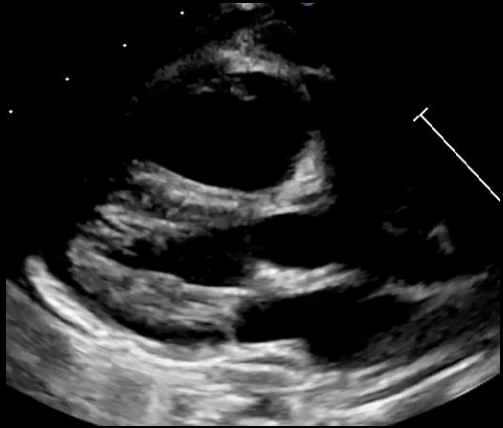-160
-80
-cm/s
-80
-160
-240

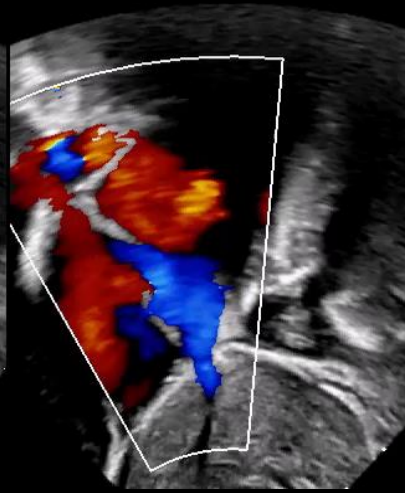
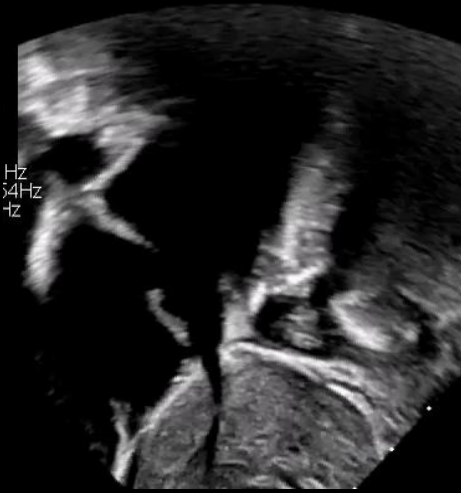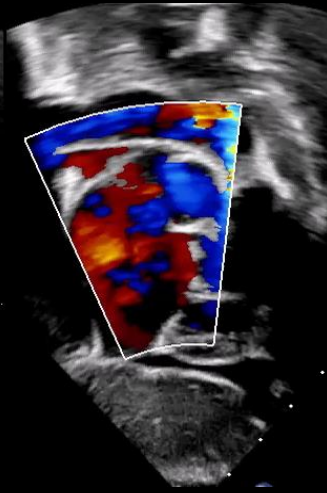
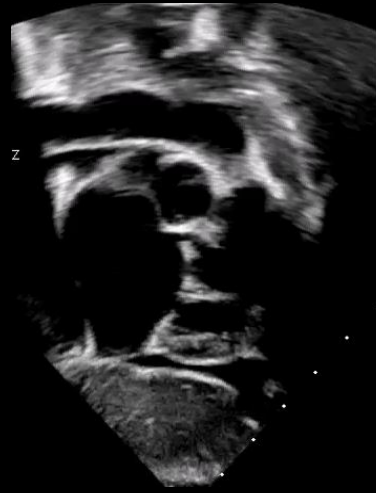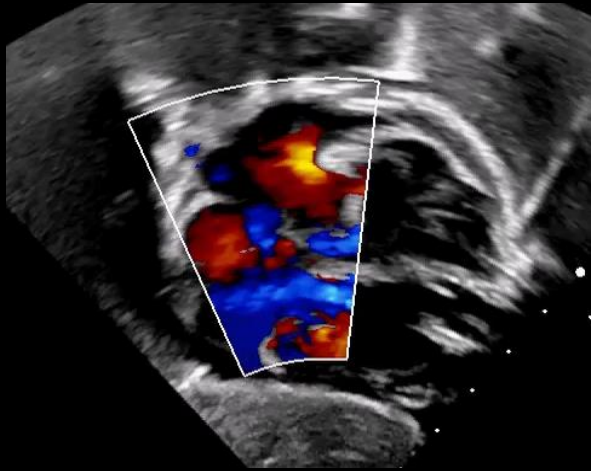


- ✓ PFO vs small secundum atrial septal defect
- ✓ Normal pulmonary artery flow acceleration
- ✓ No branch pulmonary stenosis

The study experienced technical challenges due to lack of patient cooperation

7 months old.....



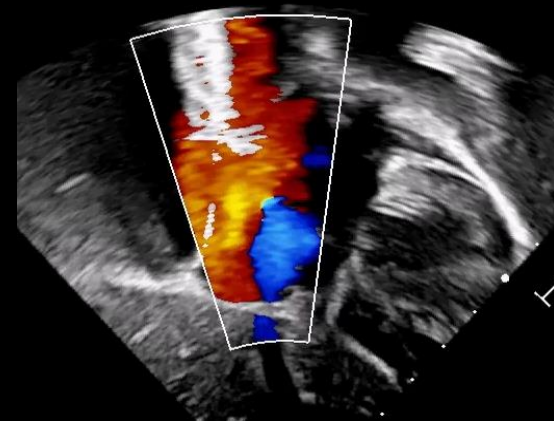
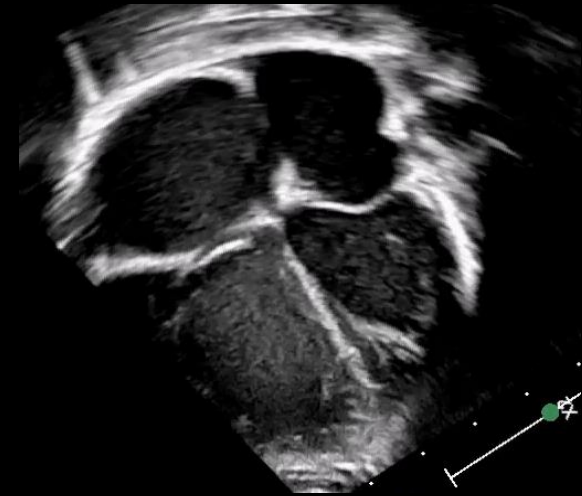
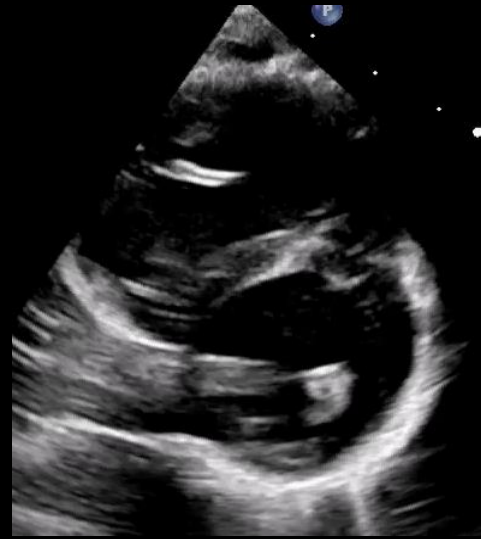
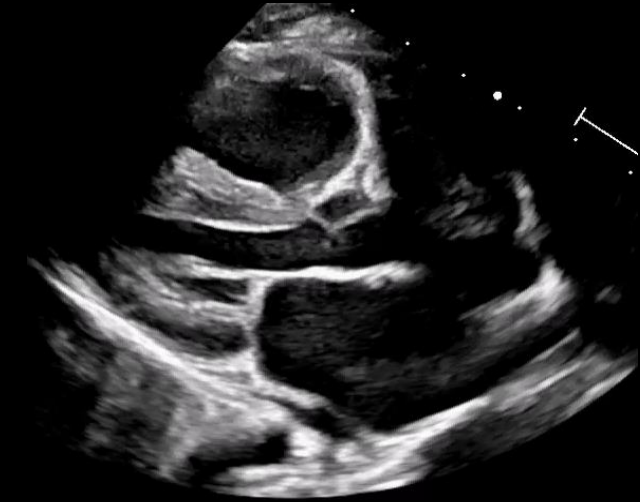
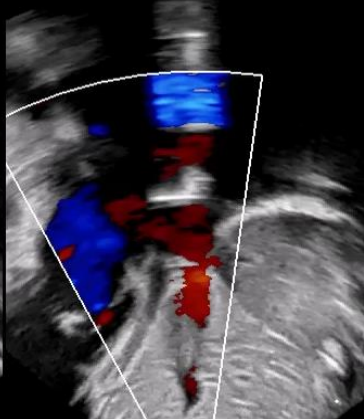
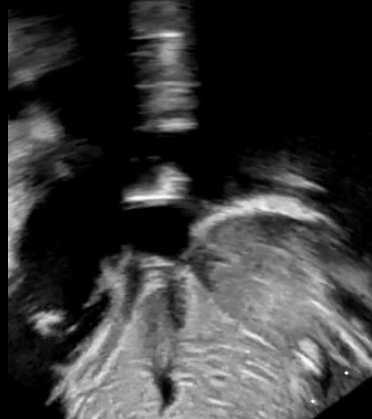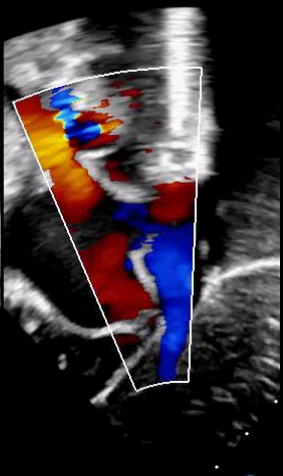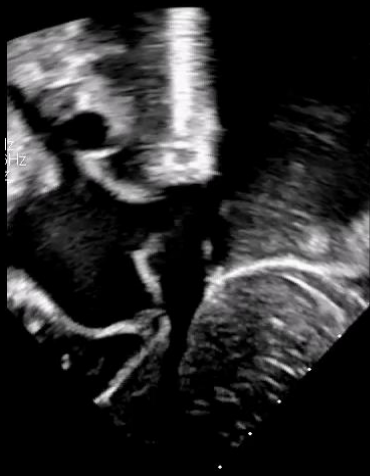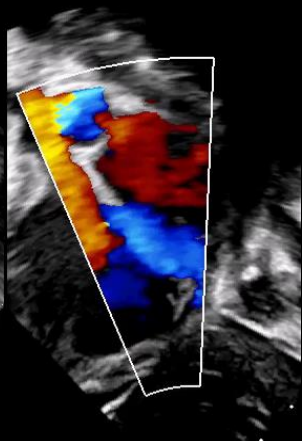
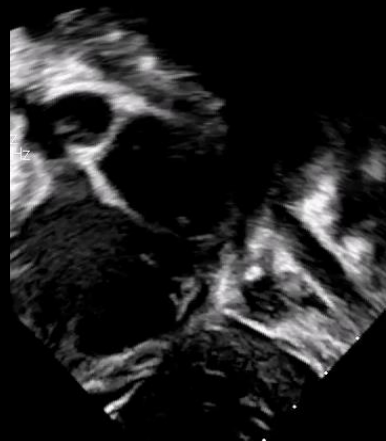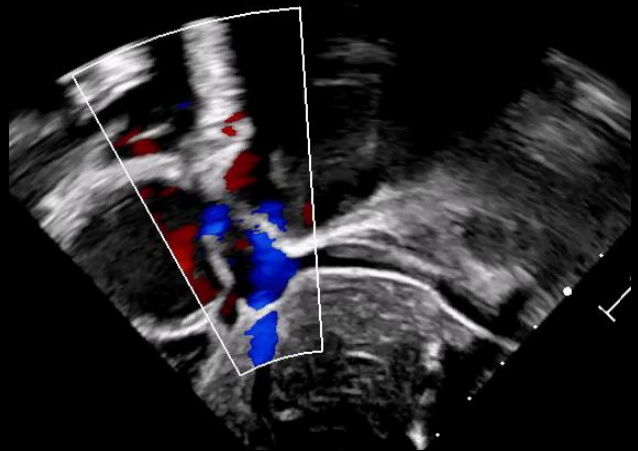
Moderate secundum atrial septal defect

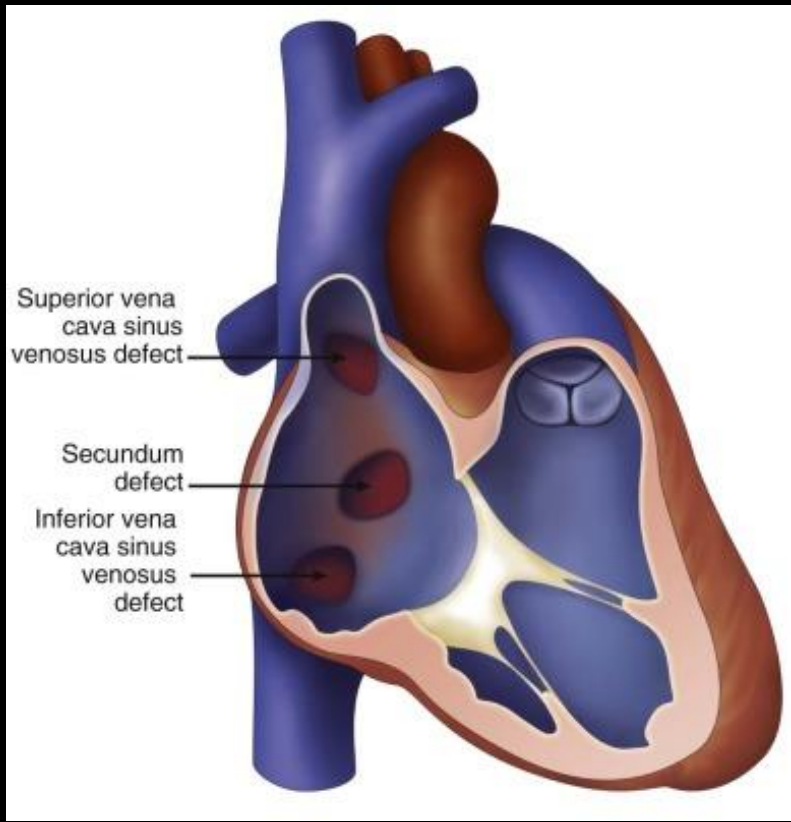
The study experienced technical challenges due to lack of patient cooperation

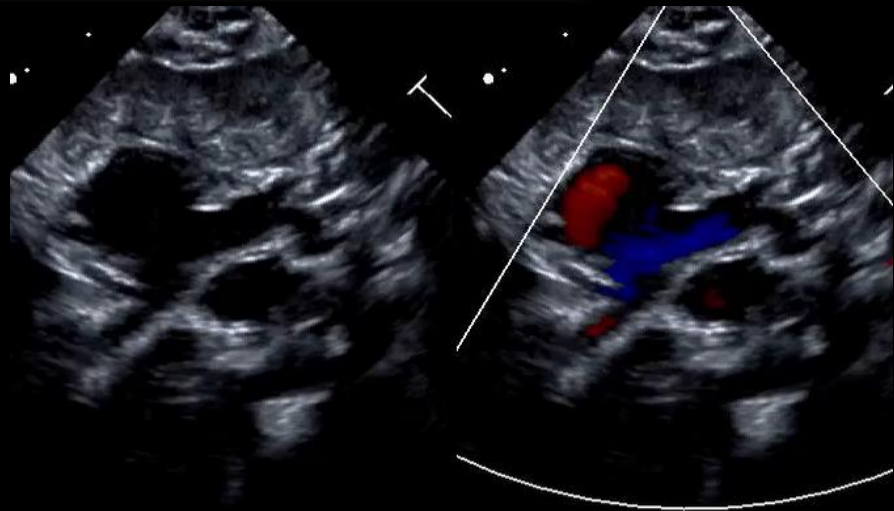
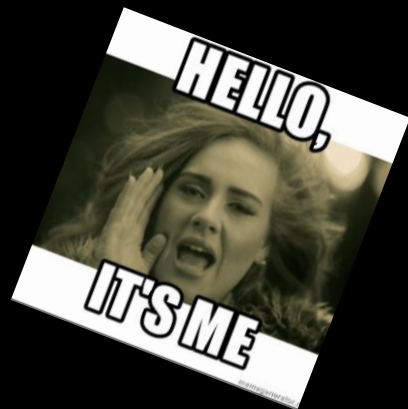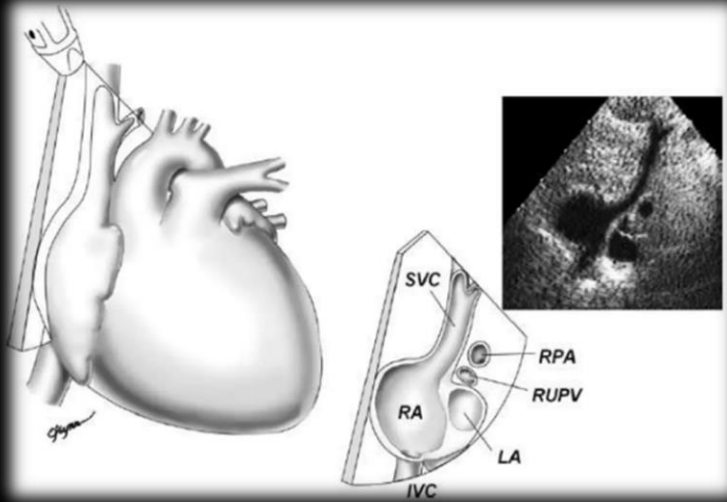
19 months old....

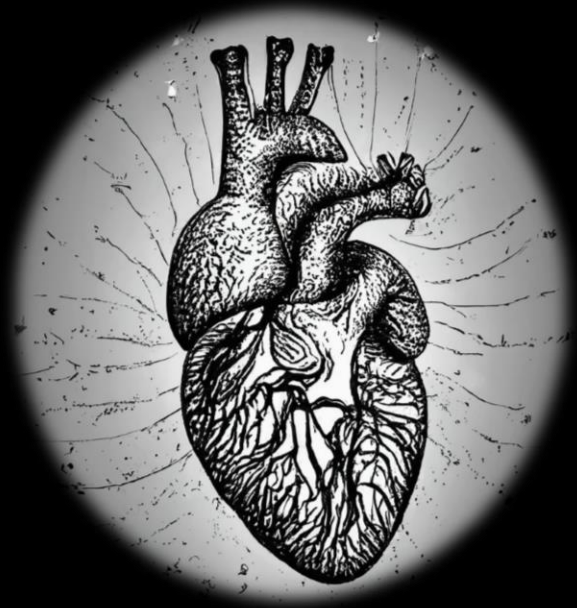
The study experienced technical challenges due to lack of patient cooperation











Thank You



NATIONWIDE CHILDREN'S

When your child needs a hospital, everything matters.